

<http://dx.doi.org/10.35630/2199-885X/2020/10/2.28>

INVESTIGATION OF MAXILLARY BONE DENSITY IN DIABETIC PATIENTS WITH CONE BEAM COMPUTED TOMOGRAPHY

Received 04 April 2020;
Received in revised form 5 May 2020;
Accepted 17 May 2020

Natalya Prozorova¹ , Roman Fadeev^{1,3✉} ,
Marina Chibisova² , Vladimir Shkarin⁴ ,
Irina Prozorova¹ , Maria Fadeeva¹,
Maxim Golubyatnikov¹, Anna Tarasenko¹ ,
Roman Maslov¹ 

¹ Department of Dentistry, Yaroslavl-the-Wise Novgorod State University, Veliky Novgorod;

² Department of Radiology in Dentistry, St. Petersburg Institute of Dentistry of Postgraduate Education, St. Petersburg;

³ Department of Orthopedic Dentistry, Mechnikov North-West State Medical University, St. Petersburg;

⁴ Department of Public Health and Health Care of Postgraduate Faculty, Volgograd State Medical University Volgograd, Russia

✉ sobol.rf@yandex.ru

ABSTRACT — The study comprises an analysis of maxillary alveolar process bone density. Dental computed tomography allows quantitative and qualitative evaluation of the bone tissue density in the jaw and serves an effective tool for assessing the bone tissue status in case of diabetes mellitus. The study showed that the structure and density of bone tissue depends on the severity of diabetes mellitus and respective complications. The study outcomes revealed a significant decrease in the bone density at the neck of the teeth in people with diabetes mellitus, whereas less pronounced changes were observed in the middle third of the teeth roots. Besides, slight changes or even an increase in density were identified around the teeth apices. Diagnostics of jawbone destruction caused by diabetes is more reliable when carried out with cone beam computed tomography.

KEYWORDS — bone tissue optical density, cone beam computed tomography, diabetes mellitus.

INTRODUCTION

According to the literature, the number of patients with diabetes in Russia has increased by more than 1 million people over the past few decades; however, the prevalence of the disease is 2–3 times as high [1].

Diabetes is a metabolic issue with a high risk of developing complications. Literature sources, for instance, point that it involves disturbed bonds of protein and mineral components, deteriorated tissue

trophism leading to a slowdown in bone remodeling, which, in turn, is responsible for its density [2, 3]. Diabetic arthropathies present a fairly frequent diabetes complication and are to be found, as certain authors claim, in 58% of patients with Type 1 diabetes and in 24% of patients with Type 2 diabetes [4]. The neurohumoral regulation system has an impact on the structure and function of musculoskeletal tissues. Therefore, excessive or insufficient production of a certain hormone, will lead, sooner or later, to the development of pathological changes in the connective tissue structure, namely in bones, joints and muscles [5, 6, 7].

At the same time, there is importance in studying the bone tissue quality parameters, including patients with Type 1 and Type 2 diabetes. The outcomes of histomorphometric analysis held through experiments involving laboratory animals with insulin deficiency, for instance, showed a decrease in the bone structure formation intensity [8, 9, 10]. In addition, a decrease in the bone trabeculae length, periosteal and endocortical surfaces of the cortical plate covered with osteoid, was revealed; another issues observed was a decrease in the number of osteoblasts, a disturbance in their function, and an increase in the apoptosis rate [11, 12, 13].

Diabetes mellitus was found to be a factor predisposing to the occurrence and development of destructive periodontal diseases, leading to the loss of gingival joint [17, 21–27]. The current theory states that in patients with Type 2 diabetes mellitus, the decisive role in the pathogenesis of inflammatory diseases of the alveolar ridge belongs to microangiopathies and acidosis due to high levels of blood glucose [16]. Lack of insulin in blood leads, on the one hand, to decreased synthesis of collagen and alkaline phosphatase by osteoblasts involved in intercellular matrix formation and mineralization, and on the other hand, to disturbed calcium absorption by small intestine microvilli and its increased excretion from the body with urine. Hypocalcemia, in turn, stimulates the parathyroid gland to release hormone, which leads to resorption and thinning of the bone tissue compact layer.

Therefore, in case of diabetes, metabolic processes in the bone structure are disrupted, the cellular elements function and organic structure change, which leads to disturbed biomechanical properties and increased risk of fracture. The mechanisms that are

presumed to partially explain the bone quality deterioration in case of diabetes mellitus, include hyperglycemia and microangiopathy [15]. The authors note that bone fragility is a consequence of insufficient exposure to insulin, and not a complication of diabetes. This means that the mechanisms underlying the developing fragility of bone tissue are similar for Type 1 and Type 2 diabetes. During that, it is not related directly to the disease and may occur long before its clinical manifestations develop.

Bone tissue of the maxilla and mandible, if viewed from the point of chemical composition and structure, reveals little difference from other human musculoskeletal system bones. However, internal rearrangement takes a much faster course in the alveolar process connective tissue if compared with other skeleton bones. Normally, the alveolar ridge height is maintained via a physiological balance between the bone formation and resorption, which are regulated not only by systemic, yet also by local factors [18, 19, 20].

Nowadays, X-ray diagnostics methods in dentistry have become an inevitable part of a comprehensive medical examination. Cone beam computed tomography (CBCT) is a relatively new method for examining the dentofacial system, which allows obtaining a high-resolution 3D model of teeth and jaws. The informational reliability of this method is much higher than the traditional 2D teeth radiography, which includes targeted intraoral X-rays and orthopantomogram. Compared to 2D X-ray images, 3D digital CBCT imaging can increase significantly the efficiency and accuracy of diagnostics, including differential diagnostics. All this is achievable since this research method enables improved differentiation of tissues and organs through cross-sectional images with high resolution without overlapping [6, 14, 28–37].

Aim of study:

to identify maxillary alveolar process bone density in patients with diabetes mellitus, employing CBCT.

MATERIALS AND METHODS

The comprehensive study involved 94 patients divided into 2 groups. Group 1 included patients with diabetes mellitus, 44 people, while Group 2 comprised 50 patients without an endocrine pathology.

The inclusion criteria for the study were: the age of 25 years and older, the presence of Type 1 or 2 diabetes in the history, no dentition defects or small (1 to 3 teeth missing) and medium (4 to 6 teeth missing) number of defects.

The criteria for not exclusion were: concomitant endocrine pathology in addition to diabetes mellitus, general diseases in the decompensation stage, cancer,

and the following dental issues: increased tooth abrasion, large dentition defects, periodontitis.

One of an exclusion criterion was refusal of a patient to join the proposed studies.

The participants' median age was 62.7 ± 1.8 , without a focus on gender differences.

The examination was carried out on a Gendex-GXCB-500 dental tomograph using the icat vision software. The optical density on the dental tomogram was evaluated with a density window (side = 3 mm). The measurements in the groups were performed in the interdental partitions of the upper jaw teeth at the levels of the middle and apex of their roots, as well as the alveoli' upper edges. The average density value was calculated automatically by the software. The density was measured in Hounsfield standard units. Measures of central tendency and data scatter were calculated employing descriptive statistics methods; quantitative parameters, depending on the distribution type, were presented as the mean value (M) and standard deviation (SD), or when estimated through nonparametric statistics — as the median (Xmed) and interquartile range QR within (LQ25% ÷ UQ75%). The analysis of the distribution type correspondence to the normal distribution law was done using the Shapiro-Wilk criterion; the critical level of significance for differences in testing statistical hypotheses was set at $p < 0.05$. To analyze the differences of the subgroups, identified through qualitative clinical diagnostic features, the non-parametric Mann-Whitney method was used. When assessing the Student criterion values, the Bonferroni correction factor was employed. The statistical processing of the obtained data was carried out using the Statistica 10, StatSoft software (identification number AGAR207F394525FA-6).

RESULTS AND DISCUSSION

As Figures 1–3 show, the most significant changes in bone density could be observed in the upper jaw teeth neck area. The bone density changes around the central part of the teeth roots were less significant. In patients with this pathology, the apex region of a number of tooth roots revealed an increase in the bone density.

A comparative analysis of the values revealed significant differences in the Gaussian density in the group of patients with diabetes, which was due to a decrease in bone density.

A nonparametric analysis revealed a range of differences in view of the median and interquartile range (QR). So, when assessing the values of the data describing the significance of differences in the upper jaw:

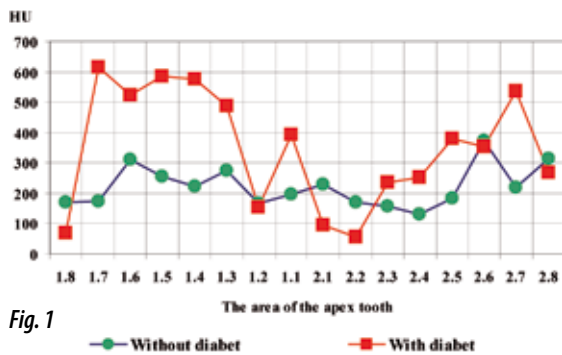


Fig. 1

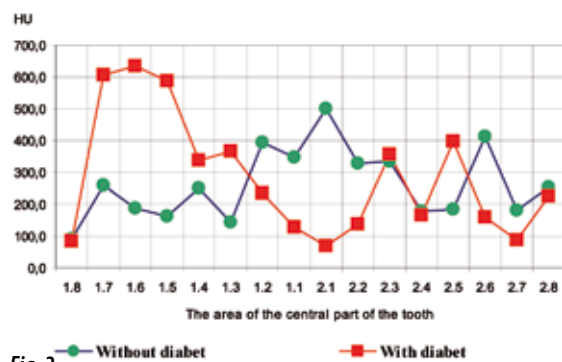


Fig. 2

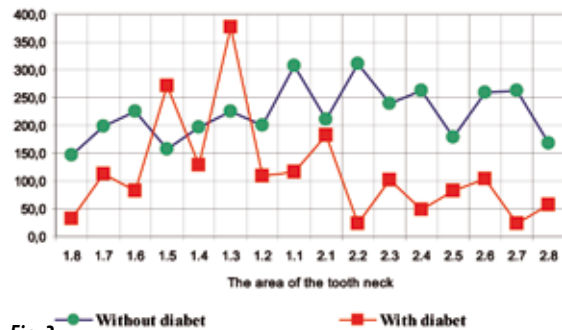


Fig. 3

Figure 1–3. Comparative characteristics of the bone tissue density (upper and lower jaws) in Hounsfield units based on Gaussian density

Upper jaw without NTG:

Tooth apex — 1.8 — Xmed = 268.0 by QR (130.5÷302.0); 1.7 — Xmed = 143.0 by QR (90.0÷263.0); 1.6 — Xmed = 266.0 by QR (124.0÷436.0); 1.5 — Xmed = 291.0 by QR (167.0÷421.0); 1.4 — Xmed = 224.0 by QR (145.0÷366.0); 1.3 — Xmed = 222.5 by QR (118.5÷392.0); 1.2 — Xmed = 155.0 by QR (100.0÷267.0); 1.1 — Xmed = 243.5 by QR (86.5÷283.0); 2.2 — Xmed = 165.5 by QR (115.0÷285.5); 2.4 — Xmed = 167.5 by QR (127.0÷257.5); 2.5 — Xmed = 257.0 by QR (173.0÷356.5); 2.7 — Xmed = 209.0 by QR (109.0÷329.0);

Central part of upper jaw tooth root — 1.8 — Xmed = 229.0 by QR (177.0÷266.5); 1.7 — Xmed = 260.5 by QR (152.0÷412.0); 1.5 — Xmed = 316.0 by QR (222.0÷385.0); 1.3 — Xmed = 301.0 by QR (264.0÷407.5); 2.2 — Xmed = 365.5 by QR (213.0÷541.0);

Tooth neck Area — 1.8 — Xmed = 299.0 by QR (234.0÷380.0); 1.7 — Xmed = 308.5 by QR (245.0÷444.0); 1.4 — Xmed = 421.0 by QR (329.0÷526.0); 2.2 — Xmed = 504.0 by QR (321.0÷631.0); 2.3 — Xmed = 293.0 by QR (221.0÷461.0); 2.4 — Xmed = 461.0 by QR (326.0÷589.0); 2.7 — Xmed = 229.0 by QR (98.0÷361.0); 2.8 — Xmed = 309.0 by QR (278.0÷445.0);

Upper jaw with NTG:

Tooth apex — 1.8 — Xmed = 168.0 by QR (141.0÷211.0); 1.7 — Xmed = 432.4 by QR (187.0÷802.0); 1.6 — Xmed = 419.0 by QR (117.3÷641.0); 1.5 — Xmed = 595.0 by QR (314.0÷901.0); 1.4 — Xmed = 402.5 by QR (123.5÷698.0); 1.3 — Xmed = 208.5 by QR (152.0÷640.0); 1.2 — Xmed = 166.0 by QR (98.0÷253.0); 1.1 — Xmed = 169.5 by QR (83.0÷475.0); 2.2 — Xmed = 148.0 by QR (115.0÷172.0); 2.4 — Xmed = 324.0 by QR (155.0÷407.0); 2.5 — Xmed = 245.0 by QR (128.5÷507.5); 2.7 — Xmed = 184.0 by QR (81.0÷617.0);

Central part of upper jaw tooth root — 1.8 — Xmed = 142.0 by QR (88.0÷172.0); 1.7 — Xmed = 190.0 by QR (47.0÷654.0); 1.5 — Xmed = 498.0 by QR (238.0÷824.0); 1.3 — Xmed = 206.0 by QR (77.0÷444.0); 2.2 — Xmed = 198.0 by QR (86.0÷223.0);

Tooth neck Area — 1.8 — Xmed = 64.0 by QR (45.0÷77.0); 1.7 — Xmed = 147.0 by QR (66.0÷179.0); 1.4 — Xmed = 157.5 by QR (76.0÷205.0); 2.2 — Xmed = 72.0 by QR (56.0÷79.0); 2.3 — Xmed = 83.0 by QR (50.0÷151.0); 2.4 — Xmed = 95.0 by QR (71.0÷120.0); 2.7 — Xmed = 92.5 by QR (84.0÷108.0); 2.8 — Xmed = 93.0 by QR (63.0÷120.0);

Similar outcomes are to be observed on dendrograms obtained through cluster analysis.

The presented data reveal significant changes in bone density according to the results of parametric and nonparametric analysis in patients with diabetes mellitus, if compared with the control group and the tooth features.

DISCUSSION

The comparative analysis carried out in the main and control groups, allowed showing that a decrease

Table 1. Bone tissue density parametric data, tooth top, upper jaw

Tooth number	M±SD	m	M±SD	m	t	P
Patients without diabetes			Patients with diabetes			
1.8	235,2±107,3	87,4	166,7±47,7	32,9	1,626*	0,0492*
1.7	193,1±124,6	103,2	479,3±362,1	286,1	-3,807*	0,0000*
1.6	284,0±163,8	140,7	418,7±320,1	250,8	-1,517*	0,0223*
1.5	302,0±158,6	134,3	566,7±294,9	232,1	-3,426*	0,0184*
1.4	252,1±138,5	116,1	449,4±348,9	299,9	-2,427*	0,0007*
1.3	255,3±143,1	124,2	395,6±345,3	288,1	-2,067*	0,0001*
1.2	187,3±127,3	102,1	238,3±249,0	152,0	-0,932*	0,0027*
1.1	218,5±133,0	108,5	291,3±283,5	221,8	-1,230*	0,0006*
2.1	227,1±146,2	124,7	196,6±195,9	137,1	0,540	0,2075
2.2	239,9±191,5	145,7	151,2±75,8	51,4	1,357*	0,0095*
2.3	270,9±120,8	98,9	306,3±161,8	129,1	-0,850	0,1638
2.4	194,1±104,2	85,1	305,7±170,6	131,0	-2,517*	0,0397*
2.5	260,6±111,1	87,1	378,1±290,6	208,7	-1,926*	0,0001*
2.6	358,2±229,9	196,2	411,8±269,1	200,3	-0,580	0,4961
2.7	223,7±127,2	101,3	307,9±258,0	210,7	-1,320*	0,0066*
2.8	238,9±181,0	148,7	292,5±144,5	129,8	-0,653	0,6504

Note: * — the reliability of statistical differences at $p < 0.05$

Table 2. Bone tissue density parametric data, central part of the tooth root, upper jaw

Tooth number	M±SD	m	M±SD	m	t	P
Patients without diabetes			Patients with diabetes			
1.8	237,0±95,1	68,8	133,6±40,4	30,8	2,781*	0,0411*
1.7	308,6±171,5	134,2	333,7±361,1	289,2	-0,281*	0,0058*
1.6	434,1±247,0	156,5	329,3±339,4	295,0	0,851	0,2688
1.5	302,8±106,9	87,2	506,6±282,3	228,4	-3,315*	0,0002*
1.4	447,4±184,1	148,3	364,8±211,3	163,5	0,987	0,5651
1.3	327,7±124,0	95,2	309,3±291,9	229,0	0,317*	0,0001*
1.2	434,0±222,2	189,0	189,5±193,5	145,8	3,203	0,6912
1.1	363,0±244,2	200,1	210,7±298,3	217,1	1,709	0,3630
2.1	473,6±256,1	227,1	181,1±329,1	193,5	2,982	0,2760
2.2	385,5±210,5	172,9	174,4±106,8	89,1	2,912*	0,0480*
2.3	475,4±265,8	188,7	314,0±242,2	209,5	2,029	0,4072
2.4	354,5±133,7	103,1	237,9±179,5	137,3	2,228	0,2124
2.5	470,4±224,4	193,8	304,0±244,2	195,8	0,649	0,1660
2.6	254,8±115,9	96,4	227,4±195,3	135,2	2,834	0,7479
2.7	304,5±170,4	143,9	132,4±54,8	44,8	2,712	0,0669
2.8	237,0±95,1	68,8	264,0±223,7	172,4	0,437	0,3879

Note: * — the reliability of statistical differences at $p < 0.05$.

in bone density can be observed in the area of the teeth neck in patients with diabetes mellitus. The least significant changes were in the area of the middle third of the teeth roots. Minor changes or even an increase

in the density were observed in the apex region. The revealed data are comparable with the outcomes presented in the national literature (Bondarenko N.N., Balakhontseva E.V., 2012, Nikolayuk V.I., Kabanova

Table 3. Bone tissue density parametric data, tooth neck, upper jaw

Tooth number	M±SD	m	M±SD	m	t	P
Patients without diabetes			Patients with diabetes			
1.8	318,5±132,9	89,5	66,9±33,5	23,8	5,244*	0,0010*
1.7	349,7±177,2	140,8	129,7±72,0	56,8	2,978*	0,0490*
1.6	400,2±281,6	200,3	176,2±144,1	101,8	1,733	0,1989
1.5	315,3±106,7	85,2	250,3±149,2	125,1	1,370	0,2010
1.4	433,5±184,1	143,3	145,2±67,6	53,4	3,753*	0,0339*
1.3	350,5±144,2	121,5	174,9±179,4	154,3	3,323	0,3250
1.2	391,5±163,7	131,7	156,0±166,3	98,2	4,077	0,8640
1.1	435,8±220,7	174,9	148,5±152,3	92,2	3,896	0,2350
2.1	430,6±235,4	134,7	130,9±107,1	93,0	5,472	0,4783
2.2	486,7±197,9	172,0	98,3±79,5	53,6	5,748*	0,0105*
2.3	426,4±463,7	245,7	129,4±118,5	85,5	3,655*	0,0260*
2.4	488,7±333,3	192,7	115,5±76,0	49,6	5,228*	0,0077*
2.5	389,5±236,8	146,7	173,8±174,9	111,9	3,018	0,5800
2.6	423,3±165,3	134,1	144,7±109,2	80,1	4,780	0,2184
2.7	281,2±195,6	153,8	101,0±59,6	37,3	2,217*	0,0144*
2.8	345,1±126,9	96,9	93,3±41,6	29,2	5,081*	0,0113*

Note: * — the reliability of statistical differences at $p < 0.05$

A.A., Karpenko E.A., 2015, Chuev V.P. et al., 2017; Khaibullina R.R. et al., 2018).

It is also notable that in the group of people with diabetes, the upper jaw bone density ranges from 151.2 to 566.7 standard units in the apical region of the teeth; from 132.4 to 506.6 standard units at the roots central part, and from 29.2 to 154.3 at the teeth neck. There was a direct dependence identified in terms of the density changes between the neck area of all teeth, especially in the area of molars, and incisors, which is accounted for by deteriorated trophic properties of periodont, inflammatory issues, and slowing bone remodeling. Changes in the area of the teeth apex were less obvious, while in the area of the teeth lateral group an inverse dependence was observed — here the bone density in people with diabetes was above that in the first group, which can be explained by reparative processes and the nature of blood supply to this area.

CONCLUSIONS

1. Cone beam computed tomography of the dentofacial segment allows a quantitative and qualitative evaluation of the optical density, as well as it also offers an effective method for evaluating the bone tissue status in case of diabetes mellitus.

2. The evaluation of the bone tissue of the upper jaw alveolar ridge, according to densitometry, showed

that changes in the bone density in case of diabetes mellitus, are symmetrical.

3. Patients with Type 1 and 2 diabetes mellitus has demonstrated a significant decrease in the upper jaw bone tissue density in the cervical region of all groups of teeth, which is due to the anatomical and physiological features of the periodontal tissue structure and the functional loads it is exposed to.

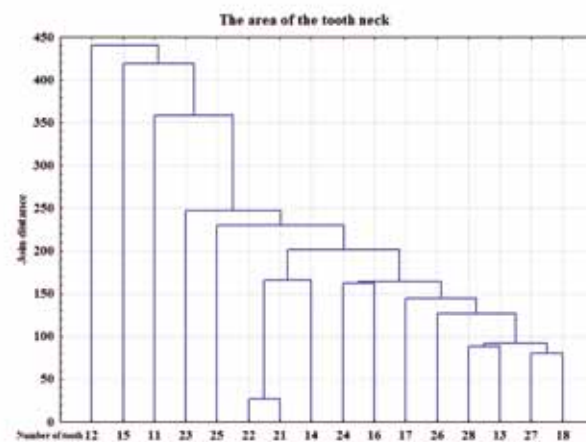
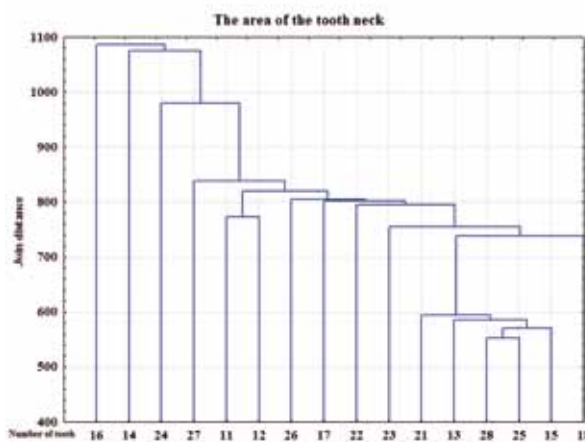
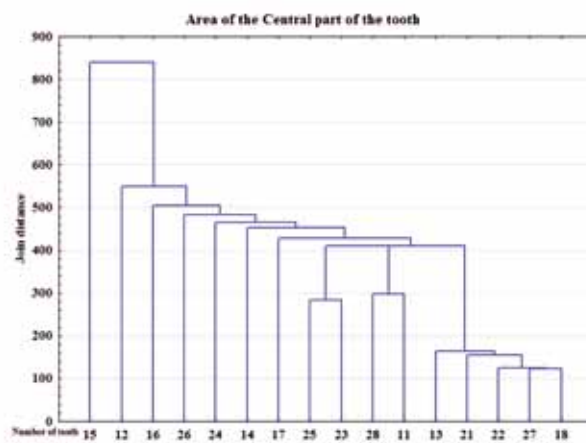
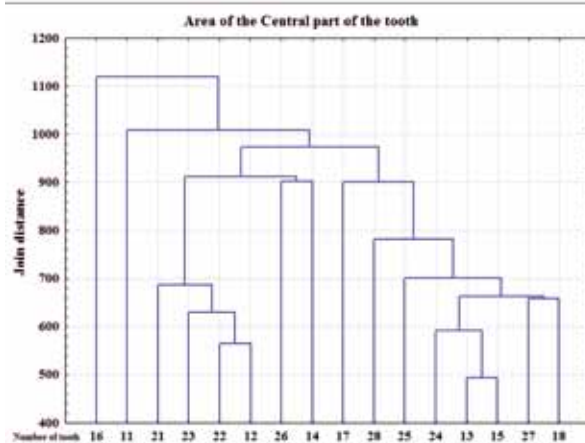
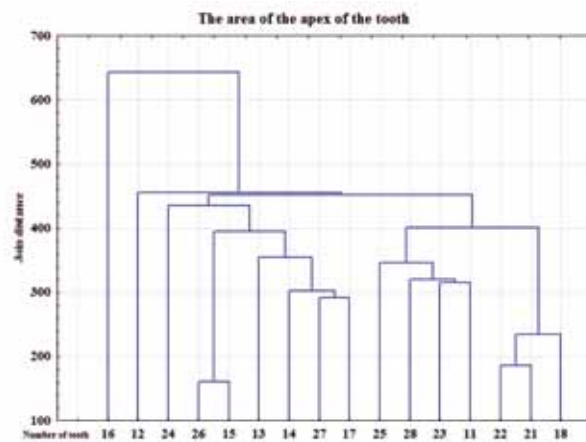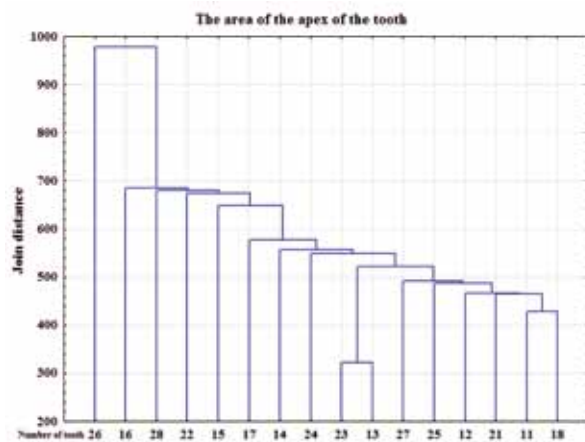4. Changes in bone density in the apical and central parts of tooth roots are less significant. A decrease in the bone density in patients with diabetes is observed in the anterior group of teeth.

5. The central area of the molars and premolars roots, as well as the tops of the upper jaw teeth in patients with diabetes mellitus reveal an increase in the bone density.

6. The study outcomes suggest that the density change is a criterion for evaluating the jaw bone tissue, as well as the most important sign that allows diagnosing and forecasting periodontal disease in people with diabetes at an early stage.

REFERENCES

1. DEDOV I. I., Endocrinology: textbook / I. I. Dedov, G. A. Melnichenko, V. V. Fadeev-M.: Litterra, 2015.– 416 pp. (In Russ.).
2. SHEPELKEVICH, A. P. Osteoporosis-a complication of diabetes, which is given insufficient attention /A.



Without diabetes

With diabetes

Figure 4. Dendrogram. Single link method. Euclidean distance. Of the optical density of the bone tissue of the upper jaw

- p. Shepelkevich, O. V. Zhukovskaya, O. A. Shakulya // Medical journal. – 2008. – No. 2. – pp. 91–95. (In Russ.).
3. Bone mineral density in patients with type 1 and type 2 diabetes / J.T. Tuominen [et al] // *Diabetes Care*. – 1999. – Vol. 2561 (22). – P. 1196–2000.
 4. Bone mineral density measured by dual x-ray absorptiometry in Spanish patients with insulin-dependent diabetes mellitus / M. Muñoz-Torres, et al // *Calcif. Tissue Int.* – 1996. – Vol. 445 (8). – P. 316–319.
 5. **HOLT S.C.** Factors in virulence expression and their role in periodontal disease pathogenesis // *Crit. Rev. Oral Biol. Med.* — 1991. — Vol. 2, N 2. — P. 177–281.
 6. **YANUSHEVICH O. O.** Dental morbidity of the population of Russia. — M.: Moscow state University of medicine, 2008. — 228 pp. (In Russ.).
 7. **VERBOVA N. I., KOSAREVA O. V.** Mineral density of bone tissue and its metabolism in type 2 diabetes mellitus in patients of older age groups^a, 2003. (In Russ.).
 8. **KEMINK, S.A.** Osteopenia in insulin-dependent diabetes mellitus; prevalence and aspects of pathophysiology / S.A. Kemink, et al. // *J Endocrinol Invest.* – 2000. – Vol. 23(5) – P. 295–303.
 9. Bone mineral density of both genders in Type 1 diabetes according to bone composition / D.J. Hadjidakis, et al // *J. Diabetes Complications*. – 2006. – Vol. 572, № 5. – P. 302–307.
 10. Glucose-induced inhibition of in vitro bone mineralization / E. Balint, et al // *Bone*. – 2001. – Vol. 1396 (1). – P. 21–28.
 11. Histomorphometry of bone tissue: myths and real possibilities / S. L. Kabak, et al. // *Health care*. – 2007. – No. 12. – pp. 21–24 (In Russ.).
 12. Histomorphometric analysis of diabetic osteopenia in streptozotocin-induced diabetic mice: a possible role of oxidative stress / Y. Hamada [et al] // *Bone*. – 2007. – Vol. 1501 (5). – P.1408–1414.
 13. Histomorphometric evaluation of the recovering effect of human parathyroid hormone (1–34) on bone structure and turnover in streptozotocin-induced diabetic rats / T. Tsuchida, et al // *Calcif. Tissue Int.* – 2000. – Vol. 464 (3). – P. 229–233.
 14. Bone and mineral metabolism in BB rats with long-term diabetes / J. Verhaeghe [et al] // *Decreased bone turnover and osteoporosis*. *Diabetes*. – 1990. – Vol. 782 (9). – P. 477–482.
 15. Extracellular glucose influences osteoblast differentiation and c-Jun expression / M. Zayzafoon, et al // *J. Cell Biochem.* – 2000. – Vol. 543 (2). – P. 301–310.
 16. Osteopenia: a bone disorder associated with diabetes mellitus / V.M. Duarte, et al // *J. Bone Mineral Metabolism*. – 2005. – Vol. 227 (1). – P. 58–68.
 17. Is insulin an anabolic agent in bone? Dissecting the diabetic bone for clues. Am. / K.M. Thrailkill, et al // *J. Physiol. Endocrinol. Metab.* – 2005. – Vol. 1238 (12). – P. 735–745.
 18. **MCCABE, L.R.** Understanding the pathology and mechanisms of type 1 diabetic bone loss / L.R. McCabe // *J. Cell Biochem.* – 2007. – Vol. 1708 (6). – P. 1343–1357.
 19. **SAFAROVA S. S.** Bone remodeling in type 1 diabetes. *Bulletin of Siberian medicine*. 2018; 17 (3): 115–121. (In Russ.).
 20. **GREBENNIKOVA, T. A., WHITE J. E., L. Y. ROZHINSKAYA ETC.** EPIGENETIC ASPECTS OF OSTEOPOROSIS. *Bulletin of the Russian Academy of medical Sciences*. 2015; 70 (5): 541–548. (In Russ.). doi.org/10.15690/vramn.v70.i5.1440.
 21. **DOMENYUK D.A., ZELENSKY V.A., RZHEPAKOVSKY I.V., ANFINOGENOVA O.I., PUSHKIN S.V.** Application of laboratory and x-ray general studies in early diagnostics of metabolic disturbances of bone tissue in children with autoimmune diabetes mellitus. *Entomology and Applied Science Letters*. 2018; 5(4): 1–12.
 22. **DOMENYUK D.A., PORFYRIADIS M.P., BUDAYCHIEV G. M-A.** Contemporary methodological approaches to diagnosing bone tissue disturbances in children with type 1 diabetes. *Archiv EuroMedica*, 2018; 8(2): 71–81.
 23. **DOMENYUK D.A., ZELENSKY V.A., DMITRIENKO S.V., ANFINOGENOVA O.I., PUSHKIN S.V.** Peculiarities of phosphorine calcium exchange in the pathogenesis of dental caries in children with diabetes of the first type. *Entomology and Applied Science Letters*. 2018; 5(4): 49–64.
 24. **DAVYDOV B.N., DOMENYUK D.A., DMITRIENKO S.V.** Peculiarities of microcirculation in periodont tissues in children of key age groups sufficient type 1 diabetes. Part I. *Periodontology*, 2019; Vol. 24; 1–24(90): 4–10. DOI: 10.25636/PMP.1.2019.1.1
 25. **DAVYDOV B.N., DOMENYUK D.A., DMITRIENKO S.V.** Peculiarities of microcirculation in periodont tissues in children of key age groups sufficient type 1 diabetes. Part II. *Periodontology*. 2019; 24(2): 108–119. (In Russ.) DOI:10.33925/1683-3759-2019-24-2-108-119
 26. **DAVYDOV B.N., DOMENYUK D.A., BYKOV I.M., IVCHENKO L.G., DMITRIENKO S.V.** Modern possibilities of clinical-laboratory and x-ray research in pre-clinical diagnostics and prediction of the risk of development of periodontal in children with sugar diabetes of the first type. Part I. *Periodontology*, 2018; Vol. 23; 3–23(88): 4–11. DOI:10.25636/PMP.1.2018.3.1
 27. **DOMENYUK D.A., SAMEDOV F., DMITRIENKO S.V., ANFINOGENOVA O.I., GLIZHOVA T.N., LYSAN D., NUZHAYAYA CH.** Matrix metalloproteinases and their tissue inhibitors in the pathogenesis of periodontal diseases in type 1 diabetes mellitus // *Archiv EuroMedica*. 2019. Vol. 9 (3). P. 81–90. <https://doi.org/10.35630/2199-885X/2019/9/9/3.25>
 28. **DOMENYUK D.A., SHKARIN V.V., PORFYRIADIS M.P., DMITRIENKO D.S., DMITRIENKO S.V.** Classification of facial types in view of gnathology // *Archiv EuroMedica*, 2017. Vol. 7 (1). P. 8–13.

29. **DOMENYUK D.A., DMITRIENKO S.V., PORFYRIADIS M.P.** Major telerehthengogram indicators in people with various growth types of facial area // *Archiv EuroMedica*. 2018. Vol. 8 (1). P. 19-24.
30. **DMITRIENKO S.V., DOMENYUK D.A., MELEKHOV S.V., DOMENYUK S., WEISHEIM L.D.** Analytical approach within cephalometric studies assessment in people with various somatotypes // *Archiv EuroMedica*. 2019. Vol. 9; 3: 103–111. <https://doi.org/10.35630/2199-885X/2019/9/3.29>
31. **DMITRIENKO S.V., FOMIN I.V., DOMENYUK D.A., KONDRATYUK A.A., SUBBOTIN R.S.** Enhancement of research method for spatial location of temporomandibular elements and maxillary and mandibular medial incisors // *Archiv EuroMedica*. 2019. T. 9 (1). P. 38–44. <https://doi.org/10.35630/2199-885X/2019/9/1/38>
32. **DMITRIENKO T.D., DOMENYUK D.A., PORFYRIADIS M.P., ARUTYUNOVA A.G., KONDRATYUK A.A., SUBBOTIN R.S.** Connection between clinical and radiological torque of medial incisor at physiological occlusion // *Archiv EuroMedica*. 2019. Vol. 9 (1). P. 29–37. <https://doi.org/10.35630/2199-885X/2019/9/1/29>
33. **SHKARIN V.V., IVANOV S.YU., DMITRIENKO S.V., DOMENYUK D.A., LEPILIN A.V., DOMENYUK S.D.** Morphological specifics of craniofacial complex in people with various types of facial skeleton growth in case of transversal occlusion anomalie // *Archiv EuroMedica*. 2019. Vol. 9; 2: 5–16. <https://doi.org/10.35630/2199-885X/2019/9/2/5>
34. **DMITRIENKO S., DOMENYUK D., TEFOVA K., DMITRIENKO T., DOMENYUK S., KONDRATYEVA T.** Modern x-ray diagnostics potential in studying morphological features of the temporal bone mandibular fossa // *Archiv EuroMedica*. 2020. Vol. 10 (1). P. 116–125. <https://doi.org/10.35630/2199-885X/2020/10/36>
35. **DOMENYUK D., DMITRIENKO S., DOMENYUK S., HARUTYUNYAN YU.** Structural arrangement of the temporomandibular joint in view of the constitutional anatomy // *Archiv EuroMedica*. 2020. Vol. 10 (1). P. 126–136. <https://doi.org/10.35630/2199-885X/2020/10/37>
36. **SHKARIN V.V., GRININ V.M., KHALFIN R.A., DMITRIENKO S.V., DOMENYUK D.A.** Specific features of transversal and vertical parameters in lower molars crowns at various dental types of arches // *Archiv EuroMedica*. 2019. Vol. 9; 2: 174–181. <https://doi.org/10.35630/2199-885X/2019/9/2/174>
37. **SHKARIN V.V., GRININ V.M., KHALFIN R.A., DMITRIENKO T.D., DOMENYUK D.A., FOMIN I.V.** Craniofacial line of telerradiography and its meaning at cephalometry // *Archiv EuroMedica*. 2019. Vol. 9; 2: 84–85. <https://doi.org/10.35630/2199-885X/2019/9/2/84>