

<http://dx.doi.org/10.35630/2199-885X/2020/10/2.25>

# METHODOLOGICAL APPROACHES TO STUDYING DENTAL ARCH MORPHOLOGY

Received 21 March 2020;  
Received in revised form 27 April 2020;  
Accepted 18 May 2020

Tatyana Kondratyeva<sup>1</sup> , Yury Harutyunyan<sup>1</sup> ,  
Dmitry Domenyuk<sup>1</sup> , Sergei Dmitrienko<sup>2</sup> ,  
Stanislav Domenyuk<sup>3</sup> 

<sup>1</sup> Stavropol State Medical University, Stavropol,

<sup>2</sup> Volgograd State Medical University, Volgograd,

<sup>3</sup> North Caucasus Federal University, Stavropol, Russia

✉ [s.v.dmitrienko@pmedpharm.ru](mailto:s.v.dmitrienko@pmedpharm.ru)

**ABSTRACT** — In order to develop a method for accelerated diagnostics of the dental arch gnathic type, we measured jaw cast models obtained from 213 people with an orthognathic bite, without congenital and/or acquired maxillofacial pathology. The difference between the actual and the calculated values of the inter-canine distance, which serves as a basis for the diagnostic method, was employed as a reference standard for mesognathic dental arches, where the triple selecting bias for the analysis of dental arches with physiological occlusion did not exceed 3 mm. The estimates for the inter-canine distance at various dental arch types (mesognathia,  $39.62 \pm 1.24$  mm; brachygnathia,  $41.50 \pm 1.15$  mm; dolichognathia,  $34.54 \pm 1.64$  mm) were obtained in view of the circle geometry, where the radius was identified by the ratio of the triple width sum of the three front teeth crowns (medial and lateral incisors and canines), to  $\pi$  value (3.14). The dental arch anterior section height was half the circle radius. Inter-canine distance was calculated subject to the Pythagorean theorem. A width change (increase) exceeding 3 mm in the anterior section allowed attributing the dental arches to the brachygnathic type, while a decrease in the said index was considered typical of dolichognathia.

**KEYWORDS** — morphometry; upper jaw; gnathic types of dental arches; mesognathia; dolichognathia; brachygnathia.

## INTRODUCTION

Lifetime X-ray and morphological diagnostics represent the major tools of research and applied value, which help solve numerous diagnostic issues faced by a number of specialists involved in public healthcare [2, 13, 16, 21, 24, 27, 31, 37, 40].

The growing interest taken currently in dentition morphometric studies is due to the systematization and specification of the accumulated data, which allows clinicians (dentists, maxillofacial surgeons) to compare the external maxillofacial parameters with the person's internal structural features not only in the normal status, yet also in case of pathological conditions [3, 10, 12, 15, 18, 23, 25, 29, 34, 39].

The anatomic features of teeth and dental arches have been the focus of numerous studies, and are of both applied and clinical value [4, 9]. There have been shown dentoalveolar segments' features with a description of the major anatomic structures, with a focus on the clinical use [8]. Knowing the maxillofacial features from the age view serves as a guideline for selecting the right method of prosthetic and orthodontic treatment, where the issues are often complicated by dental arches defects [5, 36]. Here we present some advanced methods for studying the main morphological maxillofacial elements [1, 11].

Many experts have already presented lots of convincing proof to the variety of shapes and sizes of dental arches with an orthognathic bite [7, 28]. There is data available on the major dimensions of dental arches for dolicho-, brachy- and mesognathia, in view of the odontometric values, namely for macro-, micro- and normodontia [6, 35].

The methods for identifying dental types are based on odontometric indicators and include determining the mean molars modulus whose value is indicative of normodontia if varies within 10.6–11.0 mm [14]. The said method is based only on the measurement of molars (large molars) in the vestibular-lingual and mesial-distal planes.

Other methods are based on measuring four incisors and there are values offered that point at normo-, macro- and microdontia [17]. The relationship of the tooth size and the craniofacial parameters can be seen from studies focusing on detecting individual normodontia [26, 39].

The said methods allow evaluating the size of certain teeth groups. It is worth saying that experts speak of the dental arch length that can be calculated through the summed width of 14 teeth crowns. The length of the dental arch varying within the range of 112–118 mm has been identified as speaking of the normodontia type of dental arches [19, 32].

Another parameter to identify the dental arch type is its gnathic element. The gnathic index, which is defined as the percentage of the diagonal and the transverse dimensions, is to be observed in people with a physiological bite [30]. It is to be noted that its digital values have been derived empirically and proven through a large number of observations. At the same time, in case of abnormal dental arch shape caused by the incisors protrusion or retrusion, it is almost impossible to identify the diagonal dimensions.

Given that, the gnathic indices for the dental arches have been proposed, which are based on the ratio of the 14 teeth crowns width sum to the dental arch transversal distal part [33]. However, the values presented by the authors are also based on measurements obtained from people with physiological occlusion. These methods are excessively complex, require numerous measurements and calculations for the dental and interdental types, as well as craniofacial measurements and a comparative-and-contrastive analysis.

Noteworthy is the opinion that experts express regarding the geometric and graphic reproduction of dental arches [22]. Of greatest importance is the Hauley-Herber-Herbst method, which is based on measuring the width of the three front teeth crowns on one of the sides (the medial and lateral incisors and the canine). The downside of this method is that the chord and length of the segment, following Hauley's calculations, correspond to the three front teeth sizes. In view of that, the correction factors were introduced where the arch lengths of the segment and the chord had different values [20]. However, this technique is acceptable only for arches of average size with the standard values of the front teeth.

#### *Aim of study:*

to develop a method for accelerated diagnostics of the dental arch gnathic type.

## MATERIALS AND METHODS

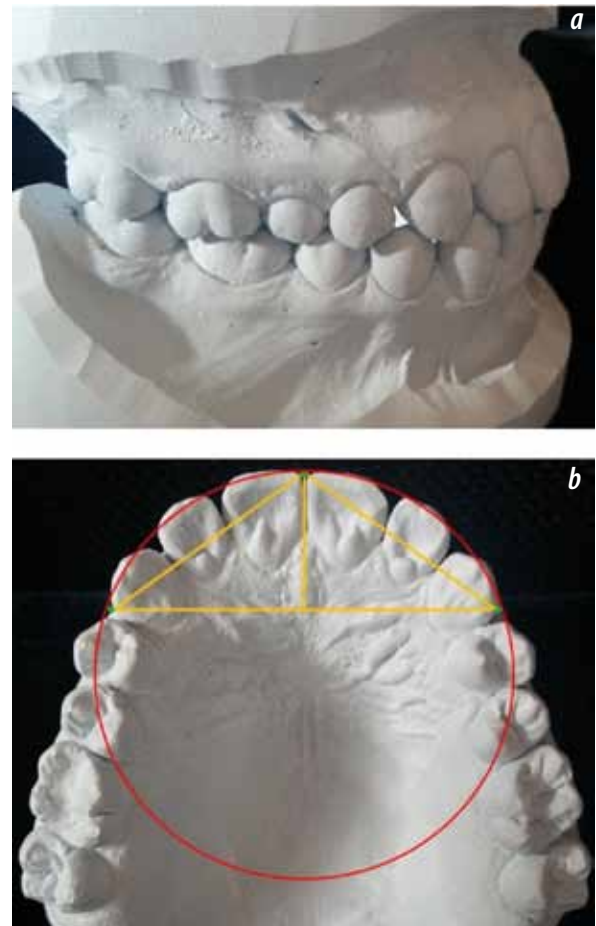
The study involved 213 people aged 20–30 with a complete set of teeth, an orthognathic bite, featuring no congenital and/or acquired maxillofacial pathology. Cast models (die stone) were obtained from all the patients' jaws. In view of the expert recommendations, the jaw models were evaluated based on the gnathic index as the ratio of the 14 teeth crowns width half-sum to the width of the distal area between the second permanent molars [30]. Subject to the index, the patients were divided into 3 groups. Group 1 included 102 patients with mesognathic dental arches; Group 2 were those with brachygnathia (59 patients), while Group 3 included another 52 patients featuring dolichognathic dental arches.

Odontometry was done using an electronic caliper (accuracy — 0.01 mm). In this case, the mesial-distal diameters of the crowns of the 14 upper teeth were measured (excluding the wisdom teeth). The transverse dimensions of the dental arch anterior section were measured between the tearing tubercles of the permanent upper canines.

The dental arch construction following the Hauley method (Hauley-Herber-Herbst) was based on

the half-sum of the width of the 6 front teeth crowns (canines and incisors). Given the construction errors associated with the fact that the radius of the circle is shorter than the chord of the segment bounded by the radius, we employed a correction taking into account the circle geometry [15]. In this case, the radius was calculated as the ratio of the triple sum of the three anterior teeth crowns width to  $\pi$  (3.14). The obtained value corresponded to the front-canine diagonal.

After making the circle, the value equal to the front-canine diagonal, was used to build the segments on both sides starting from the circle upper point. The location of these points allowed identifying the inter-canine width of the dental arch anterior part (Fig. 1).



**Fig. 1.** Physiological occlusion (a) and the analysis method for the upper jaw model (b)

In order to avoid the graphic construction of the Hauley arch, we employed the Microsoft Excel software for the estimated inter-canine distance. In this case, the Hauley data with correction coefficients

were used [15]. The anterior dental arch depth corresponded to the chord half of the anterior segment, like a right triangle leg opposite an angle of 30 degrees. Besides, the chord corresponded to the calculated radius of the circle and the front-canine diagonal. Knowing the depth of the arch and the chord value, the value of the second leg — which was half the width of the dental arch anterior section between the canines — was calculated following the Pythagorean theorem.

The difference between the actual and calculated indicators of the width of the anterior section of the dental arch was regarded as the value of inter-canine correspondence or inconsistency.

## RESULTS AND DISCUSSION

A comparative analysis of the major indicators for the dental arches of various gnathic types revealed that the average size of the teeth in the groups did not differ, which pointed at the similarity within the groups in terms of their odontometric features. Besides, we observed no significant differences in the front teeth size.

At the same time, there is a difference in the dental arches transverse dimensions that is to be noted, both in the anterior and in the distal section.

Table 1 offers a view on the cast model details in the groups in question.

A similar situation was to be observed when analyzing the transversal dimensions of the dental arch anterior section. The inter-canine distance in mesognathia was  $39.62 \pm 1.24$  mm; in those with brachygnathia the similar value was  $41.50 \pm 1.15$  mm, which was significantly above ( $p \leq 0.05$ ) that same index in people with dolichognathic dental arches ( $34.54 \pm 1.64$  mm).

The greatest diagnostic value belongs to the mismatch between the actual inter-canine distance and the calculated indicators. In Group 1 — mesognathic dental arches — we observed no significant difference between the indicators of the anterior dental arch transversal size and the calculated values.

We employed this parameter as a reference for mesognathic dental arches. The triple error of the preliminary analysis representativeness for dental arches with the physiological occlusion did not exceed 3 mm.

Given that, an increase in the anterior section width by more than 3 mm allowed us to attribute the dental arches to the brachygnathic type, whereas a decrease by the said value was indicative of dolichognathia.

Therefore, the value of the inter-canine mismatch can be used as the major criterion for accelerated diagnostics of the dental arch gnathic type.

**Table 1.** The major indicators of teeth and dental arches in the studied groups, ( $M \pm m$ ,  $p < 0.05$ )

Major indicators	Teeth and dental arch parameters		
	Group 1	Group 2	Group 3
Width sum for 14 teeth crowns (mm)	$115.57 \pm 3.29$	$112.92 \pm 2.84$	$113.16 \pm 3.12$
Width between second molars (mm)	$62.85 \pm 2.14$	$67.12 \pm 2.17$	$59.02 \pm 2.24$
Dental arch gnathic index	$0.92 \pm 0.02$	$0.84 \pm 0.03$	$0.95 \pm 0.01$
Width sum for 3 front teeth (mm)	$24.01 \pm 1.16$	$23.05 \pm 1.24$	$23.44 \pm 1.37$
Actual inter-canine width (mm)	$39.62 \pm 1.24$	$41.50 \pm 1.15$	$34.54 \pm 1.64$
Estimated inter-canine width (mm)	$39.73 \pm 0.96$	$38.14 \pm 1.03$	$38.78 \pm 1.59$
Inter-canine mismatch (mm)	$-0.11 \pm 0.83$	$4.24 \pm 0.92$	$-3.36 \pm 0.29$

The largest transversal sizes of the upper dental arches' distal part were observed in people with brachygnathic dental arches (Group 2) where their size was  $67.12 \pm 2.17$  mm. In this case, the gnathic index of the upper jaw dental arch was the lowest ( $0.84 \pm 0.03$ ) and indicative of brachygnathia.

In case of dolichognathia (Group 3), the dental arches were significantly narrower at the second molars ( $59.02 \pm 2.24$  mm,  $p \leq 0.05$ ), whereas the arch index was much higher ( $0.95 \pm 0.01$ ,  $p \leq 0.05$ ).

## CONCLUSIONS

1. A method for accelerated diagnostics of dental arches odontometric parameters and linear dimensions has been proposed and tested, which can be employed to evaluate the dental arch type. The method relies on the difference between the actual and the estimated inter-canine distance. The parameter was used as a reference for mesognathic dental arches, where the triple error in the dental arches analysis representativeness for

- physiological occlusion did not exceed 3 mm.
2. The inter-canine distance for mesognathic dental arches was  $39.62 \pm 1.24$  mm; in people with brachygnathia, the value was  $41.50 \pm 1.15$  mm, which was significantly above ( $p \leq 0.05$ ) that in people with dolichognathic dental arches ( $34.54 \pm 1.64$  mm).
  3. The estimated inter-canine distance values were obtained in view of the circle geometry, where the radius was calculated through the ratio of the triple sum of the three front teeth crowns widths (the medial and lateral incisors and the canine) to the  $\pi$  value (3.14). The height of the anterior dental arch was half the circle radius. The inter-canine distance was identified following the Pythagorean theorem. An increase in anterior section width by more than 3 mm proved to be a reliable criterion allowing attributing the dental arches to the brachygnathic type, while a decrease in the indicated value — to the dolichognathic type.
  4. The introduction of an additional criterion (the inter-canine mismatch), as the major indicator for accelerated diagnostics of the dental arches gnathic type, will allow identifying individual features in the structure of dental arches; preventing potential relapse of a dentoalveolar pathology, as well as achieving optimal predictable functional and aesthetic outcomes through orthodontic treatment.

## REFERENCES

1. **BORODINA V.V., DOMENYUK D.A., WEISHEIM L.D., DMITRIENKO S.V.** Biometry of permanent occlusion dental arches – comparison algorithm for real and design indicators // *Archiv EuroMedica*. 2018. Vol. 8 (1). P. 25–26. <https://doi.org/10.35630/2199-885X/2018/8/1/25>
2. **DAVYDOV B.N., DOMENYUK D.A., DMITRIENKO S.V., KOROBKEEV A.A., ARUTYUNOVA A.G.** Morphological peculiarities of facial skeleton structure and clinical and diagnostic approaches to the treatment of dental anomalies in children in the period of early change. *Pediatric dentistry and prophylaxis*. 2019; Vol. 19; 1 (69): 26–38. (In Russ.) DOI: 10.33925/1683-3031-2019-19-69-26-38.
3. **DMITRIENKO S.V., DOMENYUK D.A., MELEKHOV S.V., DOMENYUK S., WEISHEIM L.D.** Analytical approach within cephalometric studies assessment in people with various somatotypes // *Archiv EuroMedica*. 2019. Vol. 9; 3: 103–111. <https://doi.org/10.35630/2199-885X/2019/9/3/29>
4. **DMITRIENKO S.V., DOMENYUK D.A., VEDESHINA E.G.** Shape individualization in lower dental arches drawn on basic morphometric features // *Archiv EuroMedica*, 2015. Vol. 5 (1). P. 11.
5. **DMITRIENKO S.V., DOMENYUK D.A., KOCHKONYAN A.S., KARSLIEVA A.G., DMITRIENKO D.S.** Interrelation between sagittal and transversal sizes of maxillary dental arches // *Archiv EuroMedica*, 2014. Vol. 4 (2). P. 10–13.
6. **DMITRIENKO S.V., DOMENYUK D.A., KOCHKONYAN A.S., KARSLIEVA A.G., DMITRIENKO D.S.** Modern classification of dental arches // *Archiv EuroMedica*, 2014. Vol. 4 (2). P. 14–16.
7. **DMITRIENKO S.V., DOMENYUK D.A., FISCHEV S.B., SUBBOTIN R.S.** Dynamics of periodontal fixing capacity through orthodontic treatment employing edgewise technique // *Archiv EuroMedica*. 2019. Vol. 9; 1: 151–152. <https://doi.org/10.35630/2199-885X/2019/9/1/151>
8. **DMITRIENKO S.V., FOMIN I.V., DOMENYUK D.A., KONDRATYUK A.A., SUBBOTIN R.S.** Enhancement of research method for spatial location of temporomandibular elements and maxillary and mandibular medial incisors // *Archiv EuroMedica*. 2019. T. 9 (1). P. 38–44. <https://doi.org/10.35630/2199-885X/2019/9/1/38>
9. **DMITRIENKO T.D., DOMENYUK D.A., PORFYRIADIS M.P., ARUTYUNOVA A.G., KONDRATYUK A.A., SUBBOTIN R.S.** Connection between clinical and radiological torque of medial incisor at physiological occlusion // *Archiv EuroMedica*. 2019. Vol. 9 (1). P. 29–37. <https://doi.org/10.35630/2199-885X/2019/9/1/29>
10. **DMITRIENKO S.V., DOMENYUK D.A., PUZDYRYOVA M.N.** Manufacturing methods for individual aligners and trainers from thermoplasts and clinical indications for their application // *Archiv EuroMedica*. 2019. Vol. 9; 1: 153–154. <https://doi.org/10.35630/2199-885X/2019/9/1/153>
11. **DMITRIENKO S.V., LEPILIN A.V., DOMENYUK D.A., KONDRATYUK A.A.** Clinical meaning of methods for identifying variability of mental prominence location // *Archiv EuroMedica*. 2019. Vol. 9; 1: 45–46. <https://doi.org/10.35630/2199-885X/2019/9/1/45>
12. **DMITRIENKO S., DOMENYUK D., TEFOVA K., DMITRIENKO T., DOMENYUK S., KONDRATYEVA T.** Modern x-ray diagnostics potential in studying morphological features of the temporal bone mandibular fossa // *Archiv EuroMedica*. 2020. Vol. 10. № 1. P. 116–125. <https://doi.org/10.35630/2199-885X/2020/10/36>
13. **DOMENYUK D., DMITRIENKO S., DOMENYUK S., HARUTYUNYAN YU.** Structural arrangement of the temporomandibular joint in view of the constitutional anatomy // *Archiv EuroMedica*. 2020. Vol. 10 (1). P. 126–136. <https://doi.org/10.35630/2199-885X/2020/10/37>
14. **DOMENYUK D.A., SHKARIN V.V., PORFYRIADIS M.P., DMITRIENKO D.S., DMITRIENKO S.V.** Algorithm for forecasting the shape and size of dent arches front part in case of their deformations and anomalies // *Archiv EuroMedica*, 2017. Vol. 7 (2). P. 105–110.



15. DOMENYUK D.A., SHKARIN V.V., PORFIRIADIS M.P., DMITRIENKO D.S., DMITRIENKO S.V. Classification of facial types in view of gnathology // *Archiv EuroMedica*, 2017. Vol. 7 (1). P. 8–13.
16. DOMENYUK D.A., DMITRIENKO S.V. PORFYRIADIS M.P. Major telerehengogram indicators in people with various growth types of facial area // *Archiv EuroMedica*. 2018. Vol. 8. № 1. P. 19–24.
17. DOMENYUK D. A., KOROBKEEV A. A., DMITRIENKO S. V., KOROBKEEVA YA. A., GRININ V. M., SHKARIN V. V. Anatomical and topographical features of temporomandibular joints in various types of mandibular arches. *Medical News of North Caucasus*. 2019;14(2):363–367. DOI – <http://dx.doi.org/10.14300/mnnc.2019.14089> (In Russ.)
18. DOMENYUK D.A., PORFYRIADIS M.P., BUDAYCHIEV G. M-A. Contemporary methodological approaches to diagnosing bone tissue disturbances in children with type 1 diabetes. *Archiv EuroMedica*, 2018; 8(2): 71–81.
19. DOMENYUK D.A., VEDESHINA E G., DMITRIENKO S.V. Correlation of dental arch major linear parameters and odontometric indices given physiological occlusion of permanent teeth in various face types // *Archiv EuroMedica*. 2016. Vol. 6 (2). P. 18–22.
20. DOMENYUK D.A., VEDESHINA E G., DMITRIENKO S.V. Mistakes in Pont (Linder-Hart) method used for diagnosing abnormal dental arches in transversal plane // *Archiv EuroMedica*. 2016. Vol. 6 (2). P. 23–26.
21. DOMENYUK D.A., DAVYDOV B.N., DMITRIENKO S.V., SUMKINA O.B., BUDAYCHIEV G. M-A. Changes of the morphological state of tissue of the paradontal complex in the dynamics of orthodontic transfer of teeth (experimental study). *Periodontology*, 2018; Vol. 23; 1–23(86): 69–78. DOI:10.25636/PMP.1.2018.1.15
22. FISCHEV S.B., PUZDYRYOVA M.N., DMITRIENKO S.V., DOMENYUK D.A., KONDRATYUK A.A. Morphological features of dentofacial area in peoples with dental arch issues combined with occlusion anomalies // *Archiv EuroMedica*. 2019. Vol. 9; 1: 162–163. <https://doi.org/10.35630/2199-885X/2019/9/1/162>
23. FOMIN I.V., DMITRIENKO S.V., DOMENYUK D.A., KONDRATYUK A.A., ARUTYUNOVA A. Effect of jaw growth type on dentofacial angle in analyzing lateral telerradiographic images // *Archiv EuroMedica*. 2019. Vol. 9; 1: 136–137. <https://doi.org/10.35630/2199-885X/2019/9/2/136>
24. KOROBKEEV A. A., DOMENYUK D. A., SHKARIN V. V., DMITRIENKO S. V., MAZHAROV V. N. Variability of odontometric indices in the aspect of sexual dimorphism. *Medical News of North Caucasus*. 2019;14(1.1):103-107. DOI – <https://doi.org/10.14300/mnnc.2019.14062> (In Russ.)
25. KOROBKEEV A.A., DOMENYUK D.A., SHKARIN V.V., DMITRIENKO S.V. Types of facial heart depth in physiological occlusion. // *Medical news of North Caucasus*. 2018. – Vol. 13 (4) – P. 627–630. (In Russ., English abstract). DOI – <https://doi.org/10.14300/mnnc.2018.13122>.
26. KOROBKEEV A.A., DOMENYUK D.A., SHKARIN V.V., DMITRIENKO S.V., WEISHEIM L.D., KONNOV V.V. Anatomical features of the interdependence of the basic parameters of the dental arches of the upper and lower jaws of man. *Medical news of North Caucasus*. 2018. – Vol. 13. (1–1). – P. 66–69. (In Russ., English abstract). DOI – <https://doi.org/10.14300/mnnc.2018.13019>
27. LEPILIN A.V., FOMIN I.V., DOMENYUK D.A., DMITRIENKO S.V., BUDAYCHIEV G.M-A. Diagnostic value of cephalometric parameters at graphic reproduction of tooth dental arches in primary teeth occlusion // *Archiv EuroMedica*. 2018. Vol. 8 (1). P. 37–38. <https://doi.org/10.35630/2199-885X/2018/8/1/37>
28. LEPILIN A.V., DMITRIENKO S.V., DOMENYUK D.A., PUZDYRYOVA M.N., SUBBOTIN R.S. Dependence of stress strain of dental hard tissues and periodontal on horizontal deformation degree // *Archiv EuroMedica*. 2019. Vol. 9; 1: 173–174. <https://doi.org/10.35630/2199-885X/2019/9/1/173>
29. PORFYRIADIS M.P., DOMENYUK D.A., ARUTYUNOVA A.G., DMITRIENKO S.V. Scanning electron microscopy and X-ray spectral microanalysis in dental tissue resistance // *Archiv EuroMedica*. 2019. Vol. 9; 1: 177–185. <https://doi.org/10.35630/2199-885X/2019/9/1/177>
30. PORFIRIADIS M.P., DMITRIENKO S.V., DOMENYUK D.A., BUDAYCHIEV G.M-A. Mathematic simulation for upper dental arch in primary teeth occlusion // *Archiv EuroMedica*, 2018. Vol. 8 (1). P. 36–37.
31. SHKARIN V., DOMENYUK D., LEPILIN A., FOMIN I., DMITRIENKO S. Odontometric indices fluctuation in people with physiological occlusion. *Archiv EuroMedica*, 2018; Vol. 8; 1: 12–18. <https://doi.org/10.35630/2199-885X/2018/8/1/12>
32. SHKARIN V.V., DOMENYUK D.A., PORFIRIADIS M.P., DMITRIENKO D.S., DMITRIENKO S.V. Mathematical and graphics simulation for individual shape of maxillary dental arch // *Archiv EuroMedica*, 2017. Vol. 7 (1): 60–65.
33. SHKARIN V.V., PORFIRIADIS M.P., DOMENYUK D.A., DMITRIENKO D.S., DMITRIENKO S.V. Setting reference points for key teeth location in case of abnormal dental arch shape // *Archiv EuroMedica*, 2017. Vol.7 (2): 111–117.
34. SHKARIN V.V., IVANOV S.YU., DMITRIENKO S.V., DOMENYUK D.A., LEPILIN A.V., DOMENYUK S.D. Morphological specifics of craniofacial complex in people with varioustypes of facial skeleton growth in case of transversal occlusion anomalie // *Archiv EuroMedica*. 2019. Vol. 9; 2: 5–16. <https://doi.org/10.35630/2199-885X/2019/9/2/5>
35. SHKARIN V.V., GRININ V.M., KHALFIN R.A., DMITRIENKO S.V., DOMENYUK D.A. Specific features of transversal and vertical parameters in lower molars crowns at various dental types of arches // *Archiv EuroMedica*. 2019. Vol. 9; 2: 174–181. <https://doi.org/10.35630/2199-885X/2019/9/2/174>

36. **SHKARIN V.V., GRININ V.M., KHALFIN R.A., DMITRIENKO S.V., DOMENYUK D.A.** Specific features of grinder teeth rotation at physiological occlusion of various gnathic dental arches // *Archiv EuroMedica*. 2019. Vol. 9; 2: 168–173. <https://doi.org/10.35630/2199-885X/2019/9/2/168>
37. **SHKARIN V.V., GRININ V.M., KHALFIN R.A., DMITRIENKO S.V., DOMENYUK D.A.** Specific features of joint space in patients with physiological occlusion on computed tomogram head image // *Archiv EuroMedica*. 2019. Vol. 9; 2: 182–183. <https://doi.org/10.35630/2199-885X/2019/9/2/182>
38. **SHKARIN V.V., GRININ V.M., KHALFIN R.A., DMITRIENKO S.V., DOMENYUK D.A.** Specific features of central point location between incisors in people with physiological occlusions // *Archiv EuroMedica*. 2019. Vol. 9; 2: 165–167. <https://doi.org/10.35630/2199-885X/2019/9/2/165>
39. **SHKARIN V.V., GRININ V.M., KHALFIN R.A., DMITRIENKO T.D., DOMENYUK D.A., FOMIN I.V.** Craniofacial line of teleradiography and its meaning at cephalometry // *Archiv EuroMedica*. 2019. Vol. 9; 2: 84–85. <https://doi.org/10.35630/2199-885X/2019/9/2/84>
40. **SHKARIN V.V., DAVYDOV B.N., DOMENYUK D.A., DMITRIENKO S.V.** Non-removable arch orthodontic appliances for treating children with congenital maxillofacial pathologies – efficiency evolution // *Archiv EuroMedica*, 2018. Vol. 8 (1). P. 97–98. <https://doi.org/10.35630/2199-885X/2018/8/1/97>