

<http://dx.doi.org/10.35630/2199-885X/2020/10/2.23>

METHOD FOR QUANTITATIVE ASSESSMENT OF DENTOFACIAL ANOMALIES IN CHILD AND ADOLESCENT ORTHODONTICS

Received 17 March 2020;
Received in revised form 6 May 2020;
Accepted 19 May 2020

Roman Fadeev^{1,3✉} , Anastasiia Lanina^{1,2} ,
Pavel Li¹ , Marina Chibisova² , Vladimir Shkarin⁴ ,
Natalya Prozorova¹ 

¹ Department of Dentistry, Yaroslav the Wise Novgorod State University, Veliky Novgorod;

² Department of Radiology in Dentistry, St. Petersburg Institute of Dentistry of Postgraduate Education, St. Petersburg;

³ Department of Orthopedic Dentistry, Mechnikov North-West State Medical University, St. Petersburg;

⁴ Department of Public Health and Health Care at Faculty of Postgraduate Education, Volgograd State Medical University, Volgograd, Russia

✉ sobol.rf@yandex.ru

ABSTRACT — The paper deals with the practical application of the AMORF method for quantitative assessment of dentofacial anomalies. The proposed method allows quantifying such signs of dentofacial issues as facial aesthetics, morphology of the skull facial part, occlusion, periodontal bone tissue resorption in the sagittal, vertical, and transverse planes, as well as functional issues, close position of the teeth, their retention, root resorption and adentia. The applied focus of the AMORF method for quantitative assessment of dentofacial anomalies allows enables to select appropriate therapeutic options, and, judging the severity of the signs at the final stages of treatment, its effectiveness can be evaluated.

KEYWORDS — quantitative assessment of dentofacial anomalies, close teeth, retention, resorption adentia, sagittal plane, vertical plane, transversal plane, orthodontic treatment of children/adolescents.

INTRODUCTION

Orthodontic treatment for children and adolescents is a serious issue since it is most often associated with active growth, while cooperation and oral hygiene issues in some cases turn a stumbling block coupling with the patient's lack of motivation. Given that, the treatment plan may have to be altered through the course more often compared to the treatment of adult patients. The authors have offered convincing proof showing an increase in the role played in clinical dentistry by morphological, anthropometric, and functional research methods [1–10].

Orthodontists, therefore, often have to answer

questions like *What is the treatment tactics if based on the severity of dentofacial anomalies?, How did the signs of dentofacial anomalies change through the treatment?, Is the treatment outcome to be seen as positive or negative?*

Maxillofacial anomalies are associated with morphological, aesthetic and occlusal signs, periodontal bone resorption, close tooth position, their retention and adentia, root resorption, as well as functional disorders. The severity of these signs can vary significantly, and a change in one of them will not necessarily lead to a proportional change in the others. Facial aesthetic features, for instance, are above all influenced by the bone structures that determine their relief. These include the upper and the lower jaws, the asymmetry of which causes the contours deformation in the middle and lower face. However, soft tissue compensation must be taken into account, too. In some clinical situations, they can mask disturbances affecting occlusion and the structure of the skull facial part, while significant occlusal disorders can come combined with significant changes in facial aesthetics [11–12].

There is an obvious need for a quantitative assessment of dentofacial anomalies as the same qualitative diagnosis may imply treatment plans that are different in the scope, timing, cost, and long-term results [13–16].

The listed signs of dentofacial anomalies should be considered in the sagittal, vertical and transverse planes [17, 18].

Quantitative methods include the DAI Aesthetic Index (Dental Aesthetic Index; Cons N. et al., 1986) and the index for assessing the need to correct dentofacial anomalies, and the ICON index (Index of Complexity, Outcome & Need; Daniels C., Richmond S., 2000). However, note to be made that they only allow assessing occlusal signs, leaving out the rest of them, which offers an incomplete image of the dentofacial anomalies [19, 20].

In view of the above, we have developed and tested (involving over 5,000 patients with dentofacial anomalies) the AMORF method for quantitative assessment (A — Aesthetics, M — Morphology, O — Occlusion, R — Resorption, F — Function), which allows distinguishing 3 degrees of severity in the aesthetic, morphological, and occlusal disorders, as well as evaluating the resorption of periodontal bone

tissue in the sagittal, vertical, and transverse planes; 3 degrees of functional disorders; close position of the teeth, their retention, root resorption, and 2 degrees of adentia.

Practical application

The severity of each dentofacial anomaly symptom is identified subject to the AMORF quantitative assessment method, with all the data entered in Table 1. Next, the total numerical indicators by blocks are identified, before treatment and at the end of that, while the final conclusion regarding the treatment effectiveness is done based on the proportion where the total numerical indicator before treatment is taken as 100%, and the total numerical indicator at the end of treatment, expressed per cent, is an indicator of the treatment effectiveness, which is interpreted as follows: up to 25)% — significant improvement; [25–45)% — largely improved; [45–65)% — mildly improved; [65–85)% — minimal improvement; [85% and above — not improved or worsened, where square brackets mean *including*, round brackets — *value is not included in the numerical range*.

from a medical history thus demonstrating the potential of the AMORF method practical application.

Patient T, 12 y.o.; self-referred; came to the clinic complaining of the upper teeth uneven position; obstructed nasal breathing and speech production. The diagnosis was: upper and lower retrognathia; anterior inclination of the lower jaw; upper and lower incisors retrusion; narrowing of the upper and lower jaws; cross bite; close position of the teeth. Table 2 shows that before treatment the major disorders included aesthetics in the sagittal and vertical planes, as well as the teeth close position — they corresponded to Degrees 2 and 3 of severity, respectively. Functional disorders were obstructed nasal breathing and speech production, which corresponded to Degree 2 of severity.

Based on the diagnostic examination and recommendations on the choice of treatment tactics, the following plan was proposed to correct the maxillofacial anomaly: 1. The palate expander on the upper jaw and at the same time the labial bumper on the lower one, in order to improve the nasal breathing as well as to correct the close position of the teeth. 2. Braces on the

Table 1. AMORF-based quantitative assessment of dentofacial anomaly signs prior to/after treatment

PLANE	A	M	O	R	F
sagittal	before/after	before/after	before/after	before/after	before/after
vertical	before/after	before/after	before/after	before/after	
transverse	before/after	before/after	before/after	before/after	
SIGN	Degree 1		Degree 2		Degree 3
close position	before/after		before/after		before/after
retention	before/after		before/after		before/after
root resorption	before/after		before/after		before/after
adentia	before/after		before/after		

Note. From here on, ordinary font is used to show the common degree of the dentofacial anomaly signs prior to the treatment; bold font is used for signs after the treatment

The AMORF quantitative assessment method allows a comprehensive assessment of morphological, aesthetic, occlusal signs, periodontal bone resorption in the sagittal, vertical and sagittal planes, as well as it offers a way to assess close position of teeth, their retention, root resorption and adentia. The proposed method, if applied in clinical practice, allows, based on the severity of certain signs, understanding the etiology and pathogenesis of the dentofacial anomaly; selecting the right treatment tactics, as well as judging its effectiveness based on the change in the severity after the treatment. Here below we are offering an excerpt

upper jaw and an occlusal splint on the lower jaw until complete inclusion of teeth 1.2 and 2.2 in the dentition. 3. Fixed braces on the lower jaw, creating multiple fissure-tubercular contacts. 4. Removing the braces; retention period and observation. The main stages of orthodontic treatment can be seen in figures 1–8.

Treatment effectiveness assessment in Patient T (Table 2) based on the AMORF quantitative assessment method: A4M2O2R0F2+3 → A2M1O1R0F0+0
 Before treatment: 13 — 100%
 After treatment: 4 — 30.77%

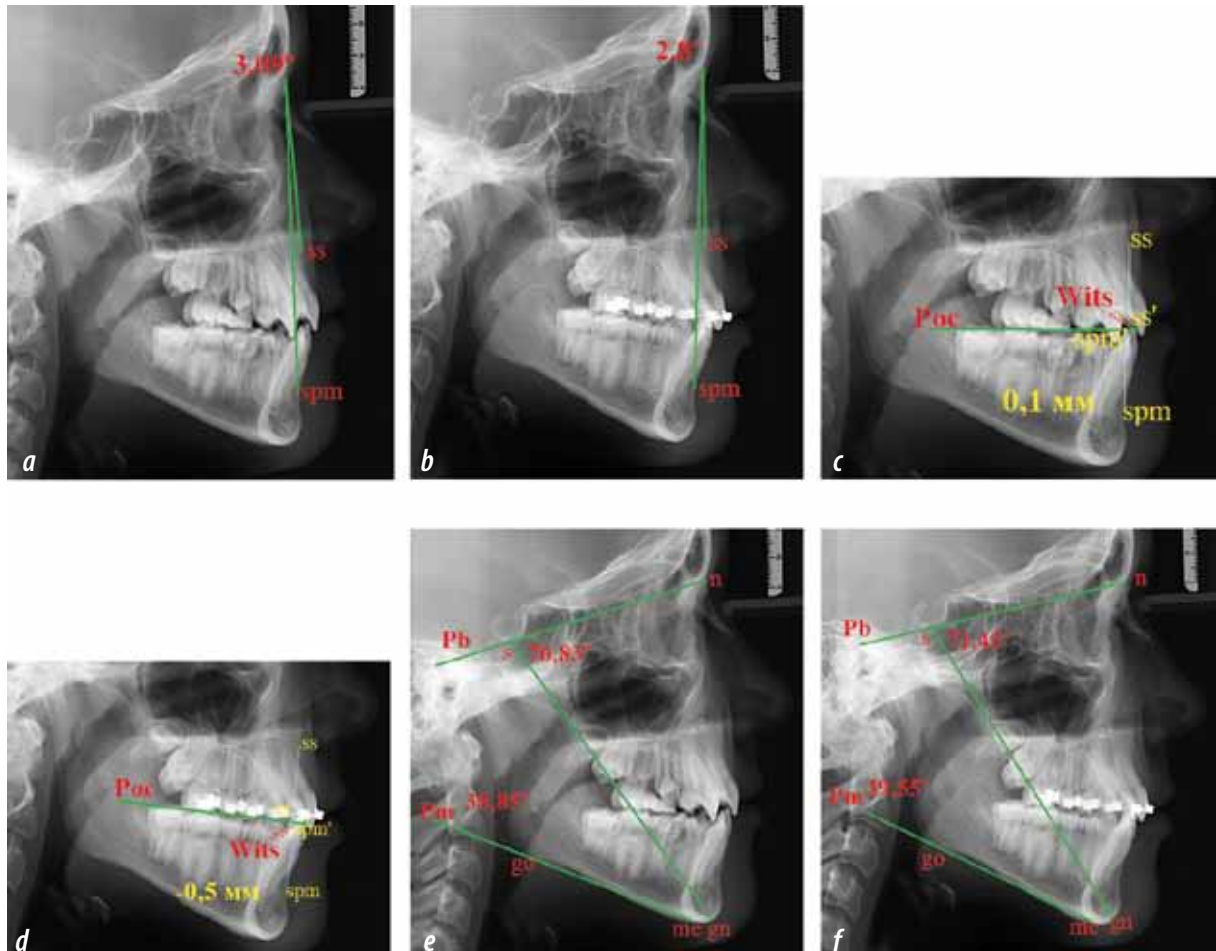


Fig. 1. Patient T's skull lateral teleradiographies, before (a, c, e) and after (b, d, f) treatment — the *ss-n-spm* angle value corresponds to Degree 1 of morphological disorders severity in the sagittal plane before treatment (a), and within norm — at the end of it (b); the *Wits* parameter values correspond to the norm before (c) and after treatment (d); the values of the *n-s-gn* and *Pm/Pb* parameters correspond to Degree 1 of morphological disorders severity in the vertical plane before treatment (e) and at its end (f)

The treatment effectiveness is interpreted here as largely improved.

CONCLUSIONS

1. In order to assess face structure disturbances, as well as treatment outcomes, it is reasonable to employ quantitative assessment methods. The proposed AMORF quantitative assessment method may be a good option.

2. Using the AMORF method of quantitative assessment for dentofacial anomalies allows choosing the orthodontic treatment tactics and, if needed, to find grounds for the treatment adjustment, as well as judging the effectiveness of the treatment upon completion.

3. Quantitative assessment of dentofacial anomalies allows demonstrating to patients and their parents the positive effect of the joint efforts taken by the doctor and the patient through the orthodontic treatment. This is especially important for growing patients, when orthodontic treatment takes long, including active growth periods of the facial part of the skull, and requires cooperation on the part of the patient when it comes to the use of intra- and extraoral devices.

REFERENCES

1. DMITRIENKO S.V., DOMENYUK D.A., MELEKHOV S.V., DOMENYUK S., WEISHEIM L.D. Analytical approach within cephalometric studies assessment in people with various somatotypes // *Archiv EuroMedica*. 2019. Vol. 9; 3: 103–111. <https://doi.org/10.35630/2199-885X/2019/9/3.29>

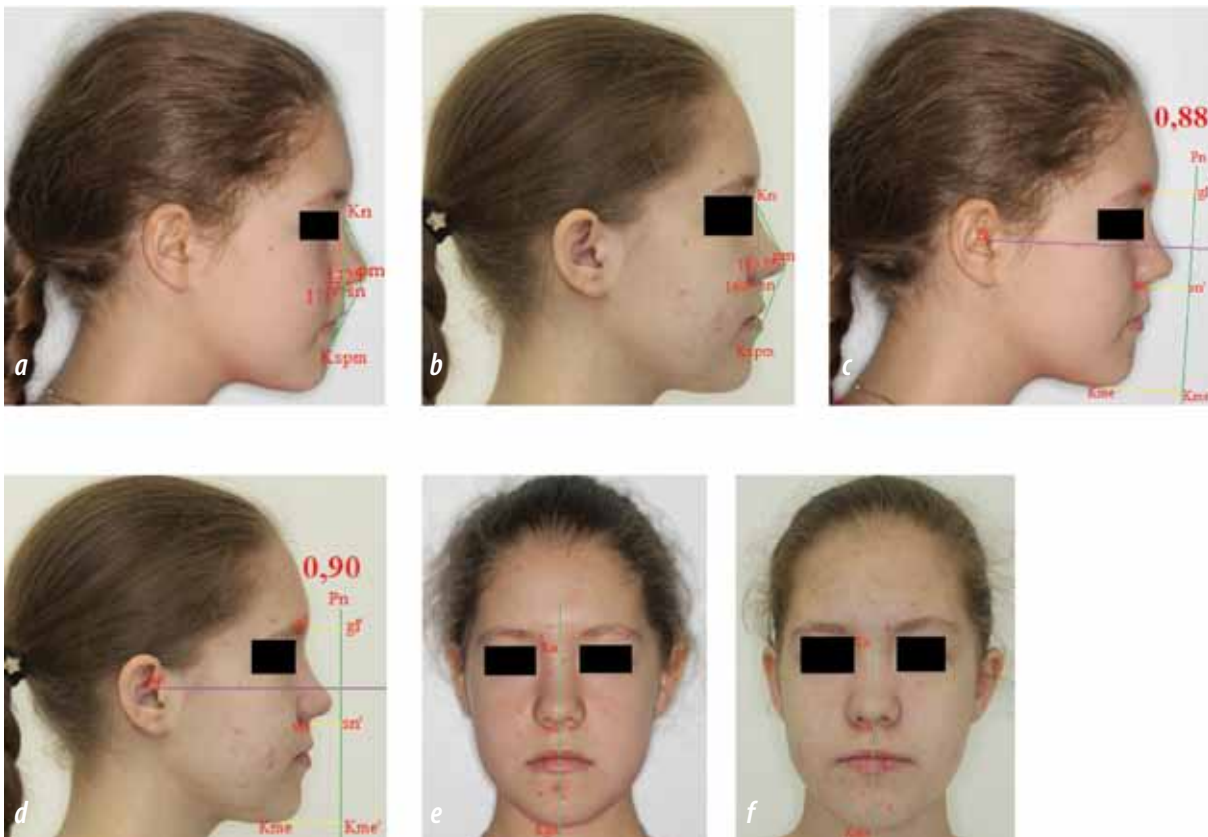

Fig. 2. Photographs of patient T's face before (a, c, e) and after (b, d, f) treatment: the $Kn-sn-Kspm$ and $Kn-prn-Kspm$ values correspond to Degree 2 of facial aesthetics severity in the sagittal plane before treatment (a) and 1 — upon its completion (b); the values of the $gn'-sn'/sn'-Kme$ relationship correspond to Degree 2 of facial aesthetics severity in the vertical plane before (c) and 1 — after treatment (d); Kgn' — ($Kn-sn$) values correspond to the norm (e, f)

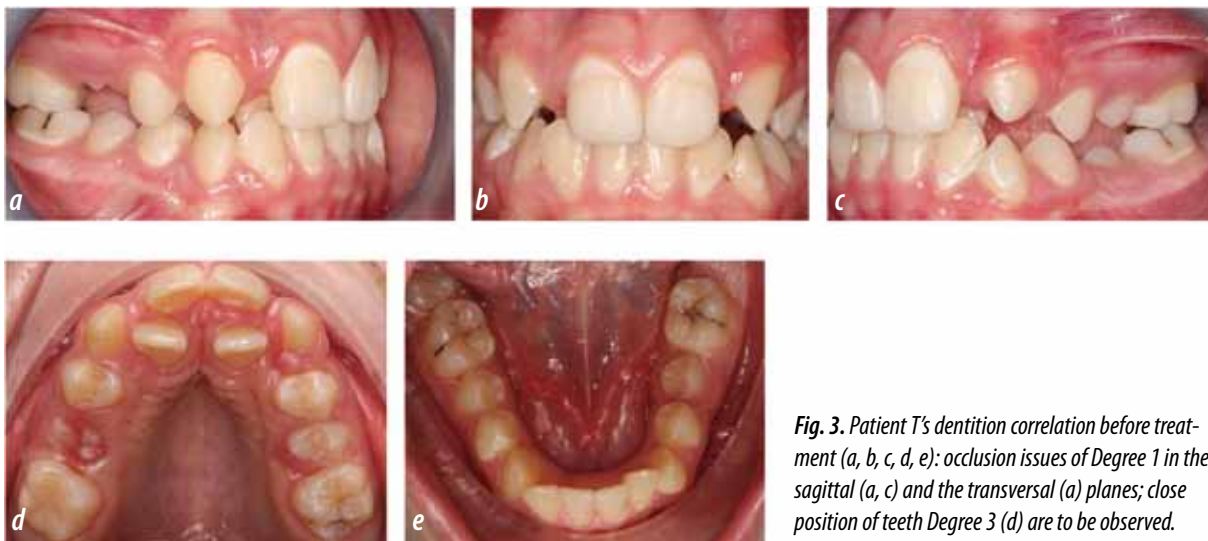


Fig. 3. Patient T's dentition correlation before treatment (a, b, c, d, e): occlusion issues of Degree 1 in the sagittal (a, c) and the transversal (a) planes; close position of teeth Degree 3 (d) are to be observed.

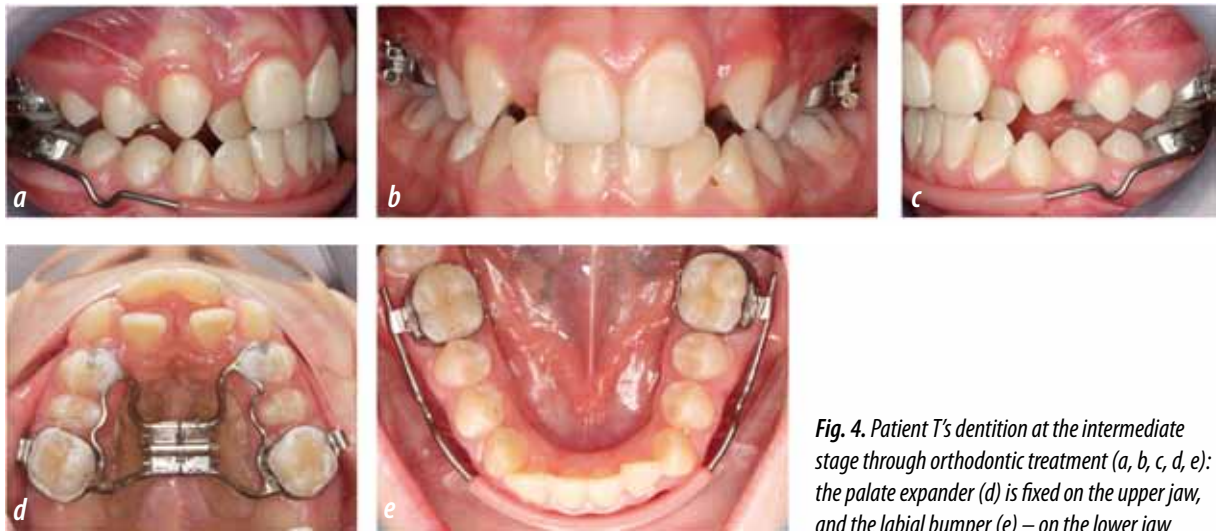


Fig. 4. Patient T's dentition at the intermediate stage through orthodontic treatment (a, b, c, d, e): the palate expander (d) is fixed on the upper jaw, and the labial bumper (e) – on the lower jaw

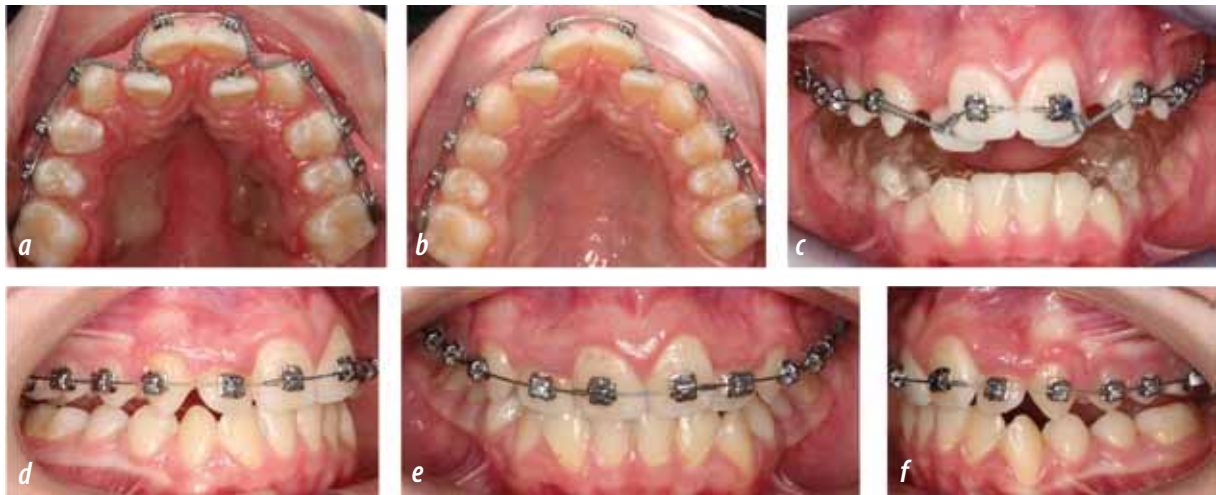


Fig. 5. Patient T's dentition at the intermediate stage through orthodontic treatment: braces (a, b, d, e, f) installed on the upper jaw, and an occlusal splint — on the lower (c)

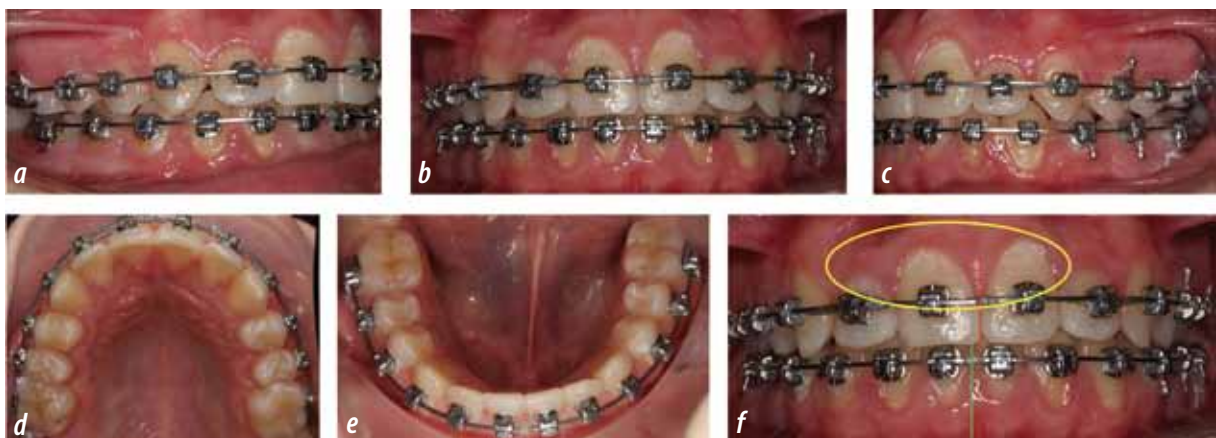


Fig. 6. Patient T's dentition before removing the braces: a slight discrepancy between the center lines of the upper and lower dentition (f) along with satisfactory fissure-tubercular contacts (a, b, c). Poor oral hygiene (f) in this case was an indication for premature removal of the device

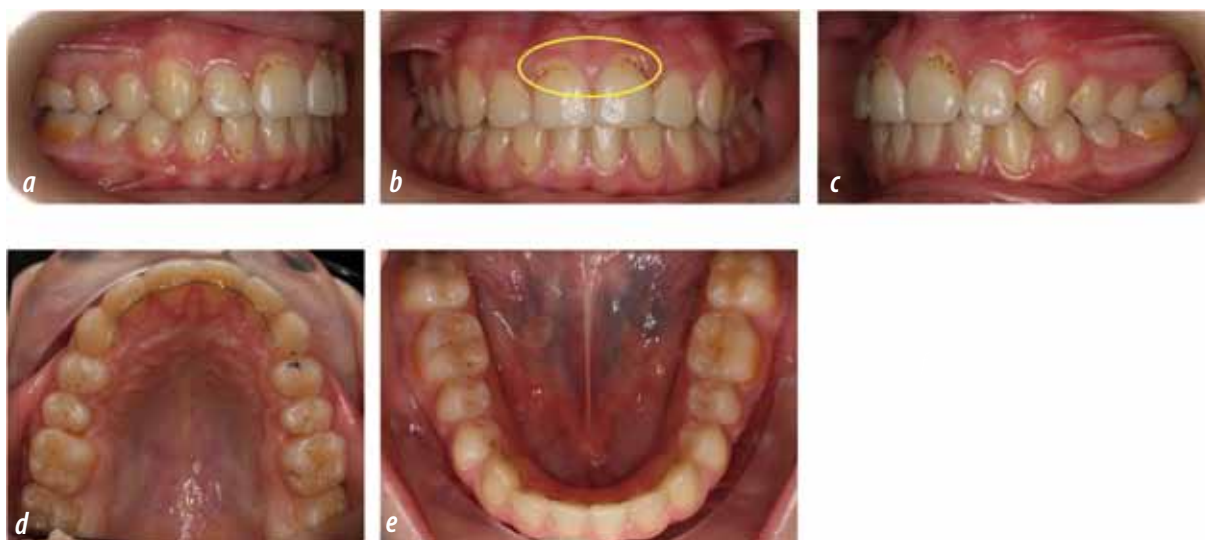


Fig. 7. Patient T's dentition one year after orthodontic treatment (a, b, c, d, e): oral hygiene got worse (b), while the dentition occlusion is stable

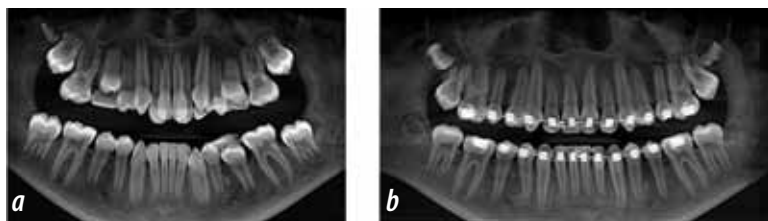


Fig. 8. Patient T's dentition CT section before treatment (a) and before the device removal (b)

Table 2. AMORF-based quantitative assessment of dentofacial anomaly signs prior to/after treatment

PLANE	A	M	O	R	F
sagittal	2/1	1/0	1/0	0/0	2/0
vertical	2/1	1/1	0/0	0/0	
transverse	0/0	---/---	1/1	0/0	
SIGN	Degree 1		Degree 2		Degree 3
close position	-----		-----		+/0
retention	-----		-----		-----
root resorption	-----		-----		-----
adentia	-----		-----		-----

- DMITRIENKO S.V., FOMIN I.V., DOMENYUK D.A., KONDRATYUK A.A., SUBBOTIN R.S. Enhancement of research method for spatial location of temporomandibular elements and maxillary and mandibular medial incisors // *Archiv EuroMedica*. 2019. Vol. 9. № 1. P. 38–44. <https://doi.org/10.35630/2199-885X/2019/9/1/38>
- DMITRIENKO T.D., DOMENYUK D.A., PORFYRIADIS M.P., ARUTYUNOVA A.G., KONDRATYUK A.A., SUBBOTIN R.S. Connection between clinical and radiological torque of medial incisor at physiological occlusion // *Archiv EuroMedica*. 2019. Vol. 9. № 1. P. 29–37. <https://doi.org/10.35630/2199-885X/2019/9/1/29>
- SHKARIN V.V., IVANOV S.YU., DMITRIENKO S.V., DOMENYUK D.A., LEPILIN A.V., DOMENYUK S.D. Morphological specifics of craniofacial complex in people with various types of facial skeleton growth in case of transversal occlusion anomalie // *Archiv EuroMedica*. 2019. Vol. 9; 2: 5–16. <https://doi.org/10.35630/2199-885X/2019/9/2/5>
- DMITRIENKO S., DOMENYUK D., TEFOVA K., DMITRIENKO T., DOMENYUK S., KONDRATYEVA T. Modern x-ray diagnostics potential in studying morphological features of the temporal bone mandibular fossa // *Archiv EuroMedica*. 2020. Vol. 10. № 1. P. 116–125. <https://doi.org/10.35630/2199-885X/2020/10/36>
- DOMENYUK D., DMITRIENKO S., DOMENYUK S., HARUTYUNYAN YU. Structural arrangement of the temporomandibular joint in view of the constitu-

- tional anatomy // *Archiv EuroMedica*. 2020. Vol. 10. № 1. P. 126–136. <https://doi.org/10.35630/2199-885X/2020/10/37>
7. **SHKARIN V.V., GRININ V.M., KHALFIN R.A., DMITRIENKO S.V., DOMENYUK D.A.** Specific features of transversal and vertical parameters in lower molars crowns at various dental types of arches // *Archiv EuroMedica*. 2019. Vol. 9; 2: 174–181. <https://doi.org/10.35630/2199-885X/2019/9/2/174>
 8. **DOMENYUK D.A., DMITRIENKO S.V. PORFYRIADIS M.P.** Major telerehthengogram indicators in people with various growth types of facial area // *Archiv EuroMedica*. 2018. Vol. 8. № 1. P. 19–24.
 9. **SHKARIN V.V., GRININ V.M., KHALFIN R.A., DMITRIENKO T.D., DOMENYUK D.A., FOMIN I.V.** Craniofacial line of teleradiography and its meaning at cephalometry // *Archiv EuroMedica*. 2019. Vol. 9; 2: 84–85. <https://doi.org/10.35630/2199-885X/2019/9/2/84>
 10. **DOMENYUK D. A., KOROBKEEV A. A., DMITRIENKO S. V., KOROBKEEVA YA. A., GRININ V. M., SHKARIN V. V.** Anatomical and topographical features of temporomandibular joints in various types of mandibular arches. *Medical News of North Caucasus*. 2019;14(2):363–367. DOI – <http://dx.doi.org/10.14300/mnnc.2019.14089> (In Russ.)
 11. Classifications of dentofacial anomalies. The system of quantitative assessment of dentofacial anomalies / R.A. Fadeev, A.N. Ispravnikova // Publishing House NL, St. Petersburg 2011, 68 p. (In Russ.).
 12. **FADEEV, R.A.** A quantitative assessment of the results of orthodontic treatment by a doctor and a patient / R.A. Fadeev, A.N. Lanina, P.V. Lee // *Orthodontics. Gnathology*. – Minsk 2019 – №1. – P. 69–75.
 13. **FADEEV, R.A.** The use of a quantitative assessment of dentofacial anomalies by a doctor and a patient for the selection and correction of treatment tactics / R.A. Fadeev, A.N. Lanina, P.V. Lee // *Institute of Dentistry*. – 2019 – №3. – P. 34–36. (In Russ.).
 14. **FADEEV, R.A.** The system of quantitative assessment of dentofacial anomalies (part 1) / R.A. Fadeev, A.N. Ispravnikova // *Institute of Dentistry*. – 2010 – №2. – P. 22–23. (In Russ.).
 15. **FADEEV, R. A.** The system of quantitative assessment of dentofacial anomalies (part 2) / R.A. Fadeev, A.N. Ispravnikova // *Institute of Dentistry*. – 2010 – №3. – P. 24–27. (In Russ.).
 16. **FADEEV, R.A.** The system of quantitative assessment of dentofacial anomalies (part 3) / R.A. Fadeev, A.N. Ispravnikova // *Institute of Dentistry*. – 2010 – №4. – P. 28–31. (In Russ.).
 17. **FADEEV, R.A.** The system of quantitative assessment of dentofacial anomalies (part 4) / R.A. Fadeev, A.N. Ispravnikova // *Institute of Dentistry*. – 2011 – №1. – P. 30–32. (In Russ.).
 18. **FADEEV, R.A.** The system of quantitative assessment of dentofacial anomalies (part 5) / R.A. Fadeev, A.N. Ispravnikova // *Institute of Dentistry*. – 2011 – №2. – P. 28–31. (In Russ.).
 19. **CONS, N.C.** DAI: The Dental Aesthetic Index. / N.C. Cons, J. Jenny, F.J. Kohout // Iowa City, Iowa: College of Dentistry, University of Iowa; 1986.
 20. **DANIELS, C.** The Development of the Index of Complexity, Outcome and Need (ICON) / C. Daniels, S. Richmond // *British J. of Orthodontics*. – 2000. – No. 2. – P. 149–162.