

## EXPERIENCE OF TREATMENT OF DIAPHYSEAL FOREARM FRACTURES IN CHILDREN BY ELASTIC INTRAMEDULLARY NAILING

**D.V. Ti-Min-Chua, N.I. Tarasov,  
V.M. Krestyashin, D.Y. Vibornov,  
A.A. Grishin, M.A. Khlebnikova**

*Pirogov Russian National Research  
Medical University;  
Filatov's Children Clinical Hospital,  
department of traumatology  
and orthopaedics,  
Moscow, Russian Federation*



**D.V. Ti-Min-Chua,**  
*traumatologist-ortopedist*



**N.I. Tarasov,** *traumatologist-  
ortopedist, head of department*



**V.M. Krestyashin,** *professor,  
traumatologist-orthopedist*

**ABSTRACT** — The article describes our experience of treatment of 51 children between the ages of 9 years 11 months 17 d 4 months with diaphyseal fractures of the forearm bones with titanium elastic intramedullary rods (TEN). The method was 10.1% of the total number of children treated with this pathology in the period from 2010 to 2016. We formulated the indications, described technique and evaluated the results of treatment. This review will be interesting for traumatologists and orthopedics and rehabilitation specialists to determine the tactics of this group of patients.

**KEYWORDS** — Pediatric traumatology, pediatric surgery, fractures of the forearm, intramedullary osteosynthesis.



**D.Y. Vybornov,** *professor,  
traumatologist-orthopedist*



**A.A. Grishin,** *traumatologist-  
ortopedist*



**M.A. Khlebnikova,**  
*anesthetist*

### INTRODUCTION

Forearm fractures are one of the most common injuries encountered in emergency pediatric traumatology. On average, according to the literature, diaphyseal localization is from 17 to 20% of fractures of this segment. Closed reposition with cast immobilization remains the "golden standard" for the treatment of fractures in children (4), but existing problems in achieving a satisfactory position of the fragments, the instability of the correction achieved determine the need for stabilizing osteosynthesis. This group of fractures is characterized by instability of bone fragments that are difficult for closed reposition and are characterized by a high risk of second-

ary displacement of fragments with the use of only external fixation. Unresolved displacement of fragments, contraction of interosseous space, instability of bone fragments can cause slow consolidation with the possible formation of nonunion fractures, or false joints, with subsequent disruption of limb function. (16). Diaphyseal localization of the fracture is a risk factor for delayed consolidation, because of the reduced intensity of bloodstream in this zone.

The use of osteosynthesis prevents secondary displacement. The results of treatment in the long-term catamnesis, including the functional result, according to the literature available to us, have not been covered. (9). The choice of the

optimal treatment option is determined not only by fracture characteristics, such as localization, type of displacement, but also by the age of the patient.

The universal fixation method has not been determined until now. (8). For a long time, the common method of choice of the surgical treatment in pediatric traumatology was open reduction with fixation of reconstructive plates or external fixation device, but recently these methods are inferior to a closed reposition with intramedullary fixation. (9).

One of the actual methods of treatment of the adolescent group of patients with diaphyseal fractures of the forearm bones is the functionally stable elastic intramedullary osteosynthesis with titanium elastic nails (TEN).

Indications for surgical treatment are diaphyseal fractures with displacement, when conservative treatment is impossible (1, 3, 12). We also identified the criteria for instability of fractures, such as: 1) The type of displacement of fragments — oblique, transverse-beveled, helical-shaped fractures; 2) Fractures of both forearm bones at different levels; 3) Localization of the fracture line in the area of muscle attachment, affecting the position of fragments; 4) Repeated repositions ("chafing" of fragments); 5) comminuted fractures, characterized by the absence of a transverse contact surface of the fragments. Advantages of this method of treatment are small operative access without exposure of the fracture zone, no need for additional immobilization during the entire period of consolidation of the fracture, and, as a consequence, early activation and rehabilitation of the patient.

## MATERIALS AND METHODS

In the department of traumatology and orthopedics of Filatov's Children Hospital from 2010 to 2016 were treated 2128 children with fractures of the forearm bones of different localization who underwent surgical treatment (Table 1). The age of the patients was from 1 year 2 months to 17 years 11 months. 1218 children were with fractures of the distal forearm bones (553 of them girls, 665 boys), which accounted for 57% of the total number of children with fractures of the forearm bones. Osteosynthesis in this group was performed by 177 patients (14%). With the diaphyseal fractures of the forearm bones were treated 504 (23%) children (of them 222 girls, 282 boys). 209 (41%) children were treated with intramedullary osteosynthesis, 51 (24.4%) of them with functionally stable elastic intramedullary osteosynthesis in the age range from 9 years 11 months to 17 years 4 months. 158 patients (75.5%) treated with K-wirefixation at the age of 3 years 1 month to 17 years 2 months. It is useful to note that there is no direct gender dependence on the

incidence of trauma. The relation of boys and girls is about 1:1.

Three of patients (0.5%) were treated with open reposition and osteosynthesis with plates because of interposition of soft tissues, ocular fractures. All children have received surgical treatment in 1–2 days from the time of injury.

## REPOSITION METHOD USING TITANIUM ELASTIC BARS (TEN)

A titanium elastic nail is a special fixation system that, due to its elastic properties and implant shape, allows achieving an anatomical and functional result that is less traumatic for the patient. To carry out the operation, a specialized set of tools is needed (fig. 1). General anesthesia. The position of the patient is on the back with the laying of the injured limb on the table. To reduce the inhalation of the patient load and increase the degree of intraoperative anesthesia performed peripheral brachial plexus block under control neyromiostimulyatora combined with ultrasound. Echographic imaging increases the effect of blockade due to the relative visualization of the position of the needle and the neurovascular bunch, which allows not only to avoid complications (damage to the structures of the brachial plexus, the introduction of an anesthetic into the vessel), but also to increase the effect of the blockadethereby enhancing and prolonging the analgesic effect in the postoperative period. Installing locks produced with periodic radioscopic control. We selected osteosynthesis rods 2.0/2.5 mm depending on the width of the medullary canal. A cutaneous incision length of 1.5–3.0 cm is performed longitudinally in the distal part of the radial and ulnar bones by 1–1.5 cm proximal to the growth zone, which is determined by radioscopic marking along the back side surface. When accessing, it is necessary to remember the anatomy of the vessels and nerves of this area (the radial artery and vein, the radial nerve), as well as the tendons and muscles (the retainer of the extensor tendons of the fingers, the tendon of the long and short muscles that remove one finger of the hand) to preserve the integrity of which delicately bred soft tissue. After exposing the surface of the bone with an acute awl at an angle of 45° to the plane of the bone in the proximal direction, we form holes for the titanium rods into the radial and ulnar bone. Before fixing the locks we produced individual modeling of the nail, which depends of the level of fracturefor creation of adequate intraosseous tension in its zone. At the time of the rod along the medullary canal through the fracture line, the presence of a technological bend can be used to correct the position of the fragments. After reaching a satisfactory position of the fragments, we perform a

Table 1. Characteristics of patients (N= 2128)

			2010	2011	2012	2013	2014	2015	2016
Distal forearm	One bone	♂	49	27	31	69	78	75	69
		♀	23	25	30	32	78	71	71
	Both bones	♂	18	16	27	42	60	55	49
		♀	9	14	23	48	54	37	38
	Total	♂	67	43	58	111	138	130	118
		♀	32	39	53	80	132	108	109
1218		Σ	99	82	111	191	270	238	227
Diaphyseal forearm	One bone	♂	5	6	10	17	17	21	33
		♀	6	7	9	11	14	18	23
	Both bones	♂	8	10	18	20	24	48	45
		♀	11	7	15	19	19	28	35
	Total	♂	13	16	28	37	41	69	78
		♀	17	14	24	30	33	46	58
504		Σ	30	30	52	67	74	115	136
Proximal forearm	Monteggia injure	♂	4	3	5	7	8	9	13
		♀	5	4	4	5	7	5	7
	Galleazzi injure	♂	1	0	1	0	2	1	0
		♀	0	0	0	1	0	0	0
	Brecca injure	♂	2	3	3	4	3	3	4
		♀	1	3	2	5	2	1	1
	Fracture of the olecranon	♂	8	4	5	7	13	10	9
		♀	4	3	5	3	10	9	7
	Fracture of the neck of the radius	♂	5	5	6	15	22	27	17
		♀	6	4	7	10	21	15	17
406		Σ	38	29	39	57	88	80	75
TOTAL			2128						

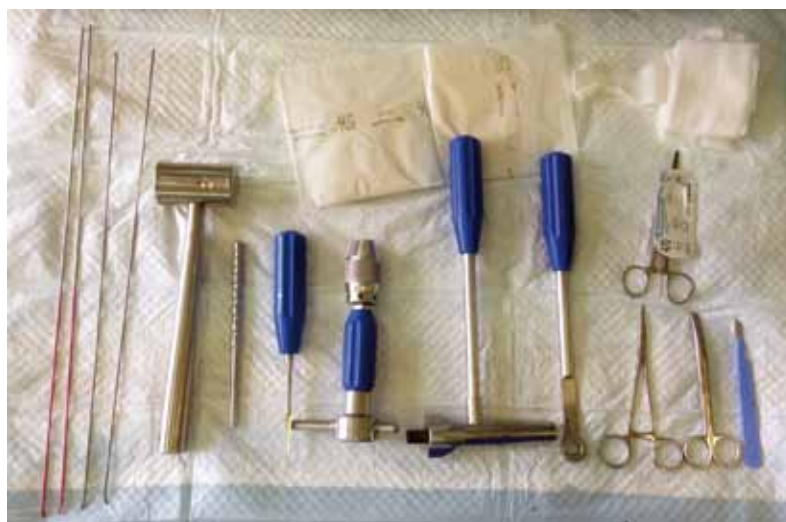

Fig. 1. Set of tools

gradual installation of rods with a turn of the ends of the rods "to each other" to create the maximum intraosseous tension in the fracture zone, and also to expand the interosseous space (fig. 2). In case the turn of the rod goes to the detriment of reposition, we chose the most correct position of the nail. Throughout the reposition, it is necessary to control not only the axial, but also the rotational displacement visually and radiologically (fig. 3). Next, the control performed X-ray, which allows us to control the position of the rod not only in the zone of fracture, but also all over the bones of the forearm. In case of violation it is necessary to determine the cause and eliminate it. After biting, the free end of the rods (about 1 cm) "fits" on the surface of the bone.

## POSTOPERATIVE MANAGEMENT

In the early postoperative period are applied bandages of the "kerchief" type for fixation within 10–14 days. The control radiograph should be performed with the capture of two adjacent joints in order to control the possible migration of the implants, the position of the fragments, and an estimate of the possible residual rotational displacement (fig. 4, 5). The main advantage of functional stable intramedullary osteosynthesis is the possibility of early activation of the injured limb.

On the stages of treatment carried out X-ray, if the child has risk factors for fracture consolidation violation carried ultrasound. In case of slow repair our speed prescribed conservative therapy and physiotherapy. In general, postoperative management of patients with diaphyseal fractures of the forearm bones is not difficult.

It should be noted that against the background of the lack of additional fixation of the limb in children with functional elastic osteosynthesis, the rehabilitation



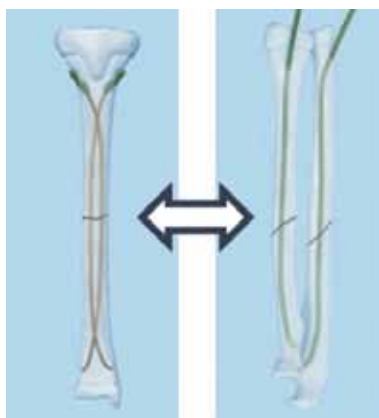


Fig. 2. Position intramedullary nails scheme

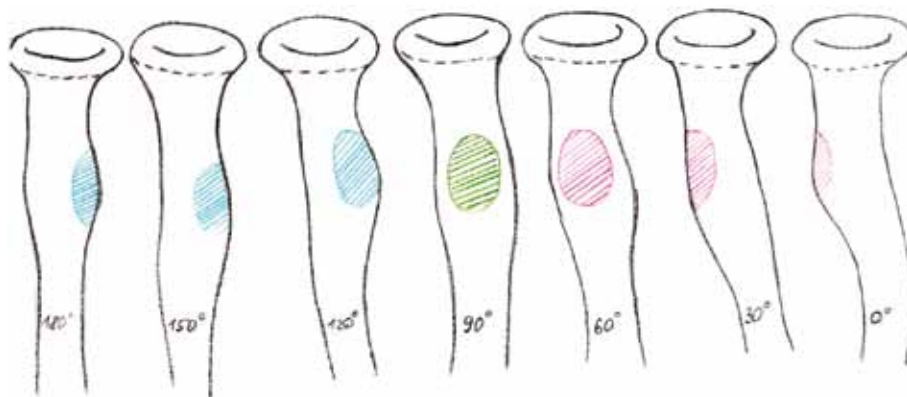


Fig. 3. Layout tuberosity of the radius for evaluating the rotational displacement (by M.Rizzo)

process was carried out in a continuous mode and the child fully utilized the injured limb in normal mode. With 5 days of post-operative patients were allowed to flexion and extension at the elbow, with 10–14 days — flexion and extension at the wrist joint, and from 3–4 weeks after the operation was being developed rotational motions after the formation of primary bone regenerate. Against this background, there were no contracture of the wrist and elbow joints, and there was also a satisfactory volume of rotational movements.

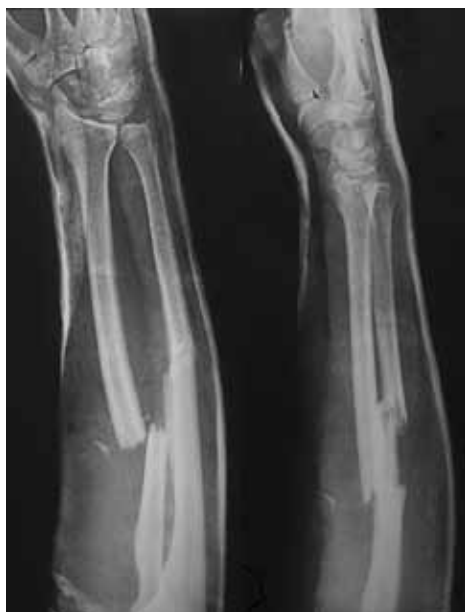

Fig. 4 Patient A., 16 y.o. X-ray of the forearm bones – comminuted diaphyseal oblique-transverse spiral both-bone fracture

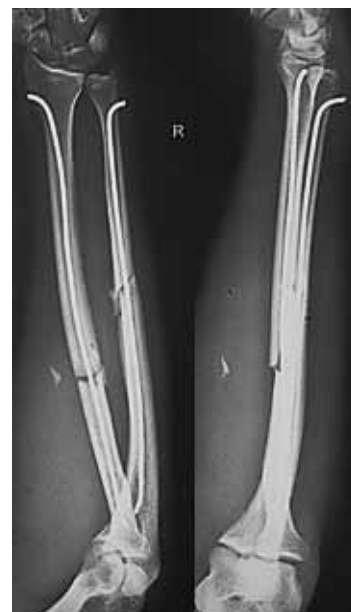

Fig. 5. The same patient. Control X-ray

### CONSOLIDATION WITH INTRAMEDULLARY OSTEOSYNTHESIS OF DIAPHYSEAL-FRACTURES OF THE FOREARM BONES

Patients of the older age group with diaphyseal fractures are in risk for developing delayed consolidation, because diaphyseal section is less blood-flowing compared to the metaepiphyseal zone of the forearm bones. Primarily, radiography is performed to

determine the state of the regenerate in the fracture zone. In case of inconsistency in the timing of the appearance of the primary bone callus in the pictures, an ultrasound (ultrasound) was ancillary. In our work, the timing of ultrasound with dopplerography to children after the installation of titanium elastic rods was as follows: 5–7, 14–17, 28–30 postoperative day. We evaluated the condition of the fracture zone, the position of the bone fragments and the diastase between them, the echostructure of the interosseous membrane, but the main information component was the intensity of the blood flow in the fracture zone, which allows us to predict the process of osteoregeneration and to give a structural assessment of bone callus based on neovascular activity of this

region. In the case of a violation of the rate of reparative osteogenesis, conservative therapy is immediately prescribed.

## RESULTS

Thus, in the period from 2010 to 2016, 504 children with diaphyseal fractures of the forearm bones were treated. The ratio of the use of osteosynthesis in fractures of the forearm bones and closed reposition is presented in Table 2. It should be noted that the younger the child, the less the probability of using osteosynthesis due to the possibilities of bone reconstruction. During this period, 295 patients were treated with closed one-stage reposition, which was 58.5% of the total number of patients with this type of injury. With the use of intramedullary osteosynthesis, 209 children were treated, which amounted to 41.4%. In 158 cases intramedullary fixation with spokes (75.5%) was applied, in 51 — functionally stable elastic osteosynthesis (24.4%). The age interval of intramedullary osteosynthesis as a whole was from 2 years 1 month to 17 years 5 months. In this case, the use of functionally stable intramedullary osteosynthesis corresponded to the older age group — from 9 years 11 months to 17 years 4 months, which is directly related to the width of the bone marrow canal, as well as the activity of the growth zones of the distal epiphyses of the radial and ulnar bones at the age of up to 8 years — with the installation of a long-standing fixation it is possible to expect its immersion deeper into the bone marrow channel due to the active growth of the child and, as a result, technical difficulties in removing it.

However, despite the more mature age, we encountered technical difficulties in removing the locks due to the too short free end of the rod left when biting after installation.

As noted above, additional immobilization during osteosynthesis by TEN is not required. We made corrections for the expressed painful syndrome and in 4 cases applied gypsum immobilization up to 10 postoperative days.

The complications revealed by us during the follow-up are presented in Table 3.

In 2 children with functionally stable intramedullary osteosynthesis (0.39%) and in 4 patients (0.25%) with intramedullary osteosynthesis, echographic data revealed delayed consolidation. These were children of the older age group, boys with fractures in the diaphysis of both forearm bones. In the process of dynamic observation, conservative therapy (Osteogenone, calcium preparations, Pentoxifylline), physiotherapeutic treatment (electromagnetic stimulation) and therapeutic physical training. Consolidation in both patients with osteosynthesis with spokes and TEN occurred

within 9 weeks, and organotypic restructuring of the osseous canal in a period of up to 6 months.

In 2 children was noted deformity of the implant at the time of 2 and 3 weeks after the operation against the background of a violation of the rehabilitation regimen — they provided an axial load on the injured limb. In one case, the child was removed rod, rheosteo-synthesis with spokes and immobilization with the cast. Osteosynthesis with K-wires was performed because of instability of bone fragments and weak intensity of bone regenerate in the fracture zone. Consolidation was observed at week 6 from the moment of repeated intervention. In the second case, the patient was also removed the rods, but against the background of a satisfactory position of fragments and a wealthy regenerate, cast was applied for 3.5 weeks, after which fracture consolidation was observed. In one case, the child was determined to violate the rotational movements throughout the entire period of wearing the rods, however, after their removal, the volume of movements is complete. In another case, a patient has a restriction of rotational movements (supination) after 1 month after removal of the implants, probably against the background of adhesion to the residual displacement.

## CONCLUSION

The functionally stable intramedullary osteosynthesis, in our opinion, corresponds to these requirements — cosmeticity, lack of additional immobilization, early functional result. For a traumatologist, such important conditions as the speed of repositioning, the convenience of the rehabilitation period, and, most importantly, early activation, that allows to avoid contractures of joints and muscle hypotrophy. Osteosynthesis with TEN is shown in the older age group — from 10 to 17 years due to the possibility of delayed consolidation and, consequently, the necessary prolonged stable fixation of the damaged segment. Patient don't need to refuse to usual everyday loads, which is important not only functionally, but also psychologically. Ultrasound evaluation of the bone regenerate state allows to determine at an early stage the slowing of the bone fragments repair rate and to prescribe conservative treatment of patients in a timely manner, which leads to the fusion of fractures in terms of 6 to 9 weeks. When determining the indications, the correct implementation of surgery and an individual approach to rehabilitation, this method is the best alternative to other surgical methods.

## REFERENCES

1. ALTAY M., AKTEKIN C.N., OZKURT B., TABAK A.Y. Intramedullary wire fixations for unstable forearm fractures in children / *Injury* 2006 Vol. 37, No. 10, P. 966–973;

Tab. 2. The ratio of the use of osteosynthesis in the treatment of fractures of the bones of the forearm (2010–2016)

	Distal forearm		Diaphyseal forearm		Proximal forearm	
	Closed reduction	Osteosynthesis	Closed reduction	Osteosynthesis	Closed reduction	Osteosynthesis
2010	86	13	20	10	28	10
2011	69	13	17	13	20	9
2012	100	11	31	21	28	11
2013	167	24	49	18	43	14
2014	205	65	51	23	70	18
2015	188	50	62	53	65	15
2016	206	21	102	34	65	10
Total	1021 (83,3%)	197 (16%)	332 (65,8%)	172 (34,1%)	319 (78%)	87 (21,4%)

Tab. 3. Complications of the method of elastic intramedullary osteosynthesis. Explanations in the text

	Number of patients	% of total number of treated patients (N=51)
Delayed consolidation	2	0,39
Deformation of the implant	2	0,39
Perforation of the skin	1	0,19
Post-traumatic neuropathy	4	0,78
Rotational contracture while wearing implants	1	0,19
Rotational contracture after removal of rods	1	0,19
Seroma region of the free end of the rod	1	0,19
Total	12	2,32

- BARRY M, PATERSON JM, A flexible intramedullary nails or fractures in children / J Bone Joint Surg. Br 2004 86: 947–53;
- LIGIER JN, METAIZEAU JP, PREVOT J, Closed flexible intramedullary nailing in pediatric traumatology. Chir Pediatr 1983; 24: 383–5
- CALDER P.R., ACHAN P., BARRY M. Dyaphyseal forearm fractures in children treated with intramedullary fixation: outcome of K-ware elastic stable intramedullary nail. Injury 2003 / Vol. 34, No. 4 p. 278–282
- CALDER P.R., ACHAN P., BARRY M. Dyaphyseal forearm fractures in children treated with intramedullary fixation: outcome of K-ware elastic stable intramedullary nail. Injury 2003 / Vol. 34, No. 4 p. 278–282
- JONES K, WEINER DS. The management of forearm fractures in children: a plea for conservatism. J Pediatr Orthop 1999; 19: 811-5
- LASCOMBES P., POPKOV DA, KOROBENIKOV AA Intramedullary elastic osteosynthesis with diaphyseal fractures in children (part 2). The genius of orthopedics № 4, 2014.
- LIGIER JN, METAIZEAU JP, PREVOT J, Closed flexible intramedullary nailing in pediatric traumatology. Chir Pediatr 1983; 24: 383-5
- MATTHEW L. VOPAT, PATRICK M. KANE, MELISSA A. CHRISTINO, JEREMY TRUNTZER, PHILIP MC-CLURE, JULIA KATARINCIC, BRYAN G. VOPAT. Treatment of diaphyseal forearm fractures in children. Orthopedic reviews, 2014 6: 5325
- METAIZEAU JP, PREVOT J, SCHMITT M, Rev Chir Orthop, 66 (1980) 47; Wortman CB, Loftus EF, Marshall ME, Psychology (McCraw-Hill Inc., New York, 1992
- METAIZEAU JP, PREVOT J, SCHMITT M, Rev Chir Orthop, 66 (1980) 47; Wortman CB, Loftus EF, Marshall ME, Psychology (McCraw-Hill Inc., New York, 1992
- PRICE C.T., KNAPP, D. R., "Osteotomy for malunited forearm shaft fractures in children", J. Pediatr. Orthop. – 2006.-vol. 26. – P. 193–196
- GOLYAKHOVSKY V., FRENKEL V., "Manual on transosseous compression-distraction osteosynthesis", M. ; SPB 1999 – 274 p.
- KOROBENIKOV AA, POPKOV DA, Intramedullary elastic stable osteosynthesis in the treatment of diaphyseal fractures of the forearm bones in children. The genius of orthopedics 2013, No. 1, P. 14–18;
- KUZNECHIKHIN EP, Surgical pathology of the upper limb in children. Manual for doctors. – M. : Publishing house BINOM, 2012. 840 p.
- NEMSADZE VP, SHASTIN NP, Fractures of the bones of the forearm in children. Moscow: Geo, 2009 – 320 p.
- PETROV M.A. "Prediction and treatment of disorders of reparative osteogenesis in children", Abstract of diss. Cand. Sciences. Moscow, 2006.
- KHODZHAEV RR, SHERMATOV GA, "Surgical methods of treatment of diaphyseal fractures of forearm bones in children, Traumatology and orthopedics of Russia 2011 – 4 (62), p. 89