

CONTEMPORARY METHODOLOGICAL APPROACHES TO DIAGNOSING BONE TISSUE DISTURBANCES IN CHILDREN WITH TYPE I DIABETES

D.A. Domenyuk, M.P. Porfyriadis, G.M.-A. Budaychiev

Department of general practice dentistry and child dentistry, Stavropol State Medical University, Stavropol, Russia

Correspondence address:

Department of general practice dentistry and child dentistry, Stavropol state medical university of Ministry of healthcare, 310, Mira Street, Stavropol, Russia 355017. E-mail: domenyukda@mail.ru, tel: +7(918)870-1205

ABSTRACT — This article focuses on issues related to bone tissue diagnostics in children with type I diabetes (different length of disease history). The results of densitometry with automatic calculation of the Z-criterion, allowed evaluating the bone tissue mineral density in the lumbar spine. The quantitative and qualitative specifics of the jaw bone tissue were based on orthopantomography and cone-beam computed tomography. The mineral and bone metabolism status was studied based on the laboratory-test data (total calcium, ionized calcium, phosphorus, alkaline phosphatase, calcitonin, osteocalcin, parathyroid hormone, 25 OH vitamin D, β -CrossLaps). The earlier stages of the disease were found to feature an increase in the bone tissue remodeling rate along with escalating bone formation intensity. The children with a long history of type 1 diabetes revealed slower bone remodeling with bone resorption dominating over bone formation, as well as a significant decrease in the mineral density with the bone tissue structure demonstrating the dominance of the criteria like *within the expected age norm and low mineral density with respect to the average age norm*.

KEYWORDS — type 1 diabetes, osteodensitometry, cone-beam computed tomography, orthopantomography, bone metabolism.

INTRODUCTION

The results of epidemiological studies carried out by the International Diabetes Federation in more than one hundred countries all over the world in the past forty years showed that type 1 diabetes is the leading condition among endocrine pathologies in children, and the current trend points at a steady increase in the incidence. These data served the basis for adopting regulatory and legal international acts aimed at combating type 1 diabetes in children (St. Vincent

Declaration of WHO, 1989; Weimar Initiative, 1997; UN Resolution, 2007) [1, 22, 24].

The worst part of type 1 diabetes developing in childhood is that the pathology affects almost all the body organs and systems; the latent nature of endocrinopathy while clinical symptoms are manifested at complete depletion of the pancreatic function; early development of severe specific complications; disturbed sexual and physical development followed with limited capacity and early disability; reduced life quality and life expectancy; premature mortality. The WHO experts claim (2012) that in case type 1 diabetes develops in childhood, such patients' life expectancy is only 50% that of the average value, while patients do not usually live beyond the age of 40. The challenge of early identification as well as high prevalence of type 1 diabetes in children explain the urgency in terms of solving problems associated with early endocrinopathy detection [2, 4, 9, 16, 23, 27].

The available scientific literature points that bone tissue is the key link in the phosphoric-calcium homeostasis system, which can be maintained through multilevel physiological systems including operational and regulatory structures that, via neurohumoral mechanisms, interact closely with each other [3, 8, 11, 12, 14, 17, 25].

Despite a lot of respective studies carried out, the data on bone tissue mineral density and phosphorus-calcium metabolism in children's type 1 diabetes are scarce and still being accumulated. There is a lot of great research and pragmatic value in the fact that, compared with the data from densitometric studies, the data on calcium-phosphorus bone metabolism obtained through lab tests are more sensitive and reveal a faster response to changes in the intensity of bone formation (bone resorption). It stands a proven fact that morphological and functional shifts observed in type 1 diabetes in the child's body correlate with changes in the calcium-phosphorus metabolism and bone mineral density. The results of laboratory and X-ray diagnostics tests for metabolic disorders of children's bone tissue with different history of type 1 diabetes will allow establishing the trend and identifying the intensity of bone formation reactions, the protective-compensatory mechanisms status, the likelihood of complications development, thus confirming the need to stick to the

principles of approaching the body as a holistic system [5, 13, 34].

All the above has laid the grounds for the aim of this study.

Aim of study:

Improving the methodological approaches in the early-stage diagnostics of type 1 diabetes in children based on phosphorus-calcium metabolism and bone mineral density.

MATERIALS AND METHODS

The study implied laboratory-clinical, X-ray examination comprising 114 children (aged 7 to 12) suffering from type 1 diabetes and undergoing treatment in the Endocrinology Department of the Filippsky Child Clinical Hospital (City of Stavropol, Russia). The duration of endocrinopathy in children diagnosed with type 1 diabetes varied from eight months to ten years. Given the disease history duration, all the patients were divided into three groups: Group 1 — duration of type 1 diabetes up to one year ($n = 33$, 28.9%); Group 2 — the disease duration 1–5 years ($n = 39$; 34.2%); Group 3 — suffering from type 1 diabetes for 5–10 years ($n = 42$, 36.9%). The comparison group included 35 healthy and basically healthy children (Yu.E. Veltishev, 1994) falling into the same age group.

The densitometric measurement of the bone mineral density relied on the dual-energy X-ray absorptiometry in the lateral and frontal projection of the lumbar spine with morphometric analysis. The examinations were performed employing the Lunar iDXA densitometer using a cadmium-zinc-telluride detector array and the High-definition direct-digital narrow-angle fan-beam technology. The enCORE™ GE Lunar software was operated on the Windows XP Professional and included a special pediatric program with age and sex normative indicators installed, which allowed a reliable assessment of quantitative changes in the child's bone system. In pediatrics, Dual-energy X-ray absorptiometry (DXA) is the gold standard for studying bone mineral density. The following bone system parameters were evaluated through the X-ray scanning:

- *Area* – the scanned section projection area (cm^2);
- *BMC* – the Bone Mineral Content (g);
- *BMD* – the Bone Mineral Density, i.e. the volume of the mineralized bone as per unit of the scanned area ($\text{BMD} = \text{BMC}/\text{Area}$) (g/cm^2).

The bone mineral density estimation (hydroxyapatite quantity per a bone surface unit) using the DXA method is an integral measurement of the cortical and trabecular bone, whereas the densitometric result

is expressed as an index of the standard deviation in relation to the normative value. Following the recommendations of the International Society for Clinical Densitometry, BMD in the pediatric DXA protocol is assessed with the Z-score, which is the standard deviation value of the actual bone mineral density with respect to the average age norm, while the terms *osteopenia*, *osteoporosis* are not employed in the DXA outcomes analysis.

The following evaluation criteria using the Z-score were used: Z-score values below one standard deviation ($< -1\text{SD}$) are described as *normal mineral density*; Z-score from one (-1SD) to two (-2SD) standard deviations are defined as *within the expected average age norm*; Z-score below two standard deviations ($< -2\text{SD}$) are referred to as *low mineral density relative to the average age or below the expected age norm*. The spine bone tissue mineral density data were compared with the reference database of the Lunar iDXA densitometer and the national standards (Scheplyagina L.A. et al, 2004).

Orthopantomography (OPG) of the jaw bones was performed on an ORTHOPHOS XG 3 DS digital orthopantomograph. The OPG analysis focused on evaluating the height, shape and condition of the cortical plate of the alveolar process and interalveolar septa, the degree of expansion of the periodontal gap, the bone tissue resorption in the jaws and in the interalveolar septa. The resorption degree of the jaw body and interalveolar septa was described with the following features: excessive transparency of the bone substance, thinned bone trabeculae, thinned cortical layer, local bone loss, restructured fiber arrangement in the bone substance. The *Fuchs index* (the quantitative index of the decrease in the alveolar bone height) the resorption degree in the interalveolar septa was established relative to the tooth root length (Fig. 1). The Fuchs index evaluation codes included: 0 — missing tooth due to periodontal pathology, or tooth outside of the bone tissue; 1 — bone resorption exceeding $\frac{2}{3}$ of the root length; 2 — bone resorption up to $\frac{2}{3}$ of the root length; 3 — bone resorption up to $\frac{1}{3}$ root length; 4 — no resorption in the alveolar process. The calculation formula:

$$\text{Fuchs index} = \frac{(n \cdot 0) + (n \cdot 1) + (n \cdot 2) + (n \cdot 3) + (n \cdot 4)}{\text{number of teeth}}$$

Scoring scale: 0 points — the interalveolar septum bone resorption reaches the tooth root apex; 0.25 points — bone resorption is above $\frac{2}{3}$ of the root length; 0.5 points — bone resorption from $\frac{1}{3}$ to $\frac{2}{3}$ of the root length; 0.7 points — bone resorption up to $\frac{1}{3}$ of the root length; 1 point — no loss of bone tissue in the interalveolar septa.

The X-ray index was used to identify the bone tissue destruction degree in the alveolar part with respect to the tooth root total length (Fig. 2). The calculation of the values and their ratios was performed with the AutoCAD Architecture software (2018 Version, 2D format).

The quantitative assessment of the mandible cortical layer was done with the mandibular cortical index (MCI) (by Klemetti E., 1994). The cortical layer was measured on both sides below the foramen mentale using a quadriplying magnifying glass bearing a millimeter grid (step — 0.1 mm) (Fig. 3).

The qualitative evaluation of the cortical plate below the foramen mentale was performed following the E. Klemetti method (1994) using the following morphological types: C1 — the inner border of the cortical plate is clear and even; C2 — the cortical layer boundary has single semilunar defects with the cortical plate dissection on one or both sides; C3 — the border is unclear, uneven, the cortical plate is multilayered, porous, with numerous defects (Fig. 4).

The cone-beam computed tomography (CBCT) was performed on a 21-slice digital panoramic PaX-i3D SC device featuring the function of a computer tomograph and FOV cephalostat with accessories subject to the scanning protocol for Sim Plant. The processing, storage and export of the X-ray images were done with the Ez Dent-i™ software; the multiplanar reconstruction and 3D reconstruction — with 3D tomography Ez Dent-iT™ software for 3D diagnostics; viewing of the saved data with an import option — using the Viewer software [6, 15, 19, 28, 31, 33]. The tomographic section thickness was 1 mm, the reconstruction step — 1 mm, the rotation step — 1 mm, the reconstruction mode was set as BONE and STDN (standard) [7, 21, 30, 32]. The radiological density of the mandibular bone was examined based on mathematical reconstruction of the attenuation coefficients expressed in Hounsfield units (HU) [10, 18, 20, 26, 29, 35]. The areas for the investigation we selected included the mandibular body at the second molar and the mandibular angle (C. Ulm, 2009). The cortical bone thickness was measured at the foramen mentale level (Fig. 5).

The COBAS 6000 Hoffmann-LaRoche Diagnostics analyzer for biochemical and immunochemical analysis (with commercial test kits) was employed to detect the level of inorganic phosphorus, calcium (total, ionized), activity of the bone isoenzyme of alkaline phosphatase (AP) in all the patients' blood serum. The contents of serum immunoreactive parathyroid hormone (PTH), osteocalcin, calcitonin, 25-hydroxyvitamin D were determined via solid-phase enzyme immunoassay (EIA) using Vector-Best commercial

test systems. The optical density of the samples was recorded on an enzyme-linked plate analyzer Statfax 4200. The bone resorption was assessed based on the serum levels of the degradation product of the C-terminal telopeptide of type I collagen spiral proteins (β -CrossLaps) using the «Serum CrossLaps™ELISA» diagnostic test systems (96 catalog number AC-02F1). The statistical data processing was performed employing the StatPlusV25 software application package using parametric and nonparametric methods.

RESULTS AND DISCUSSION

Table 1 shows the radiographic features of the jaw bone tissue status in the groups involved.

Table 2 shows the radiological density of the mandibular body bone tissue in the groups under examination.

The outcome analysis reveals that the increase in the duration of type 1 diabetes in children comes along with a significant decrease in the radiographic density of bone tissue in the mandibular angle (body), a decrease in the interalveolar septa height and the width (thickness) of the mandible cortical layer, associated with an increase in the share of patients featuring a slightly (type C2) or severely damaged (type C3) cortical layer (Fig. 6).

Thus, the children with an endocrinopathy history of up to one year (the Fuchs index for the group 0.87 ± 0.06 ; X-ray index 0.03 ± 0.01 ; MCI 3.7 ± 0.1 ; X-ray density, body of lower jaw 263.5 ± 102.8 HU; X-ray density, angle of lower jaw 539.1 ± 126.3 HU) and from 1 to 5 years (the Fuchs index for the group 0.75 ± 0.07 ; X-ray index 0.08 ± 0.01 ; MCI 3.5 ± 0.2 ; X-ray density, body of lower jaw 39.2 ± 127.4 HU; X-ray density, angle of lower jaw 156.3 ± 71.8 HU) revealed a uniform, insignificant, generalized decrease in the interalveolar septa height (less than $\frac{1}{3}$ of the root length), combined with an early degree of resorption (3–8%) of the bone tissue. The children with a 5–10 year-long history of type 1 diabetes (the Fuchs index for the group 0.68 ± 0.08 ; X-ray index 1.14 ± 0.02 ; MCI 3.4 ± 0.1 ; X-ray density, body of lower jaw 126.7 ± 133.8 HU; X-ray density, angle of lower jaw 5.6 ± 37.4 HU) featured a uniform generalized decrease in the interalveolar septa height (within $\frac{1}{3}$ of the root length) at the initial resorption degree (14%) of bone tissue.

The results of the study of computer tomograms of cross-sections of the alveolar part of the mandible of healthy children allow to visualize the integrity of the trabecular packet, wide cortical plates (vestibular, lingual, palatine), the presence of interconnected wide trabeculae (Fig. 7a). In the studied images of bone sections in children with experience of type 1 diabetes from 1 to 5 years, damage to the trabecular packet

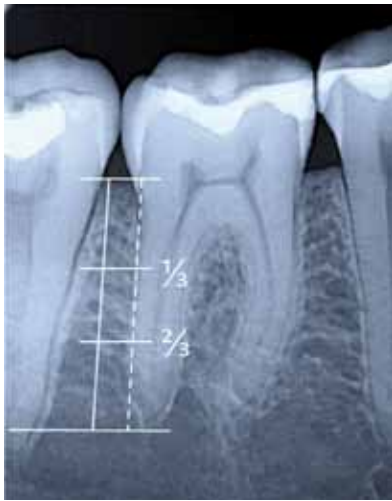

Fig. 1. The method of quantitative determination of the degree of resorption of interalveolar partitions relative to the length of the root (Fuchs index)

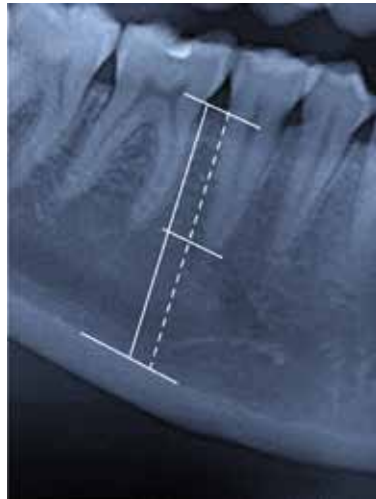


Fig. 2. The method of quantitative determination of the degree of bone tissue destruction of the alveolar part relative to the root length (X-ray index)

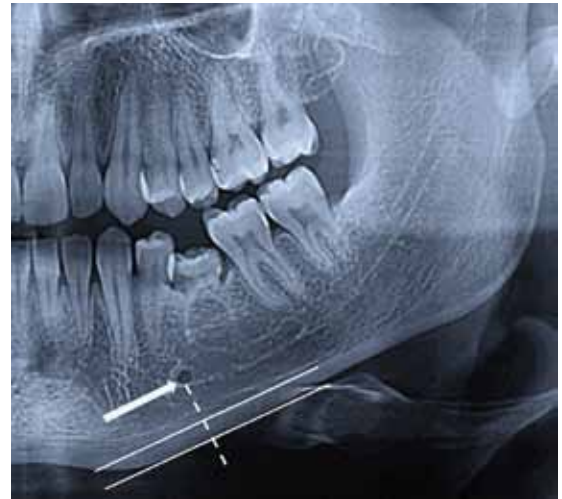


Fig. 3. Method of quantitative determination of the thickness of the cortical layer of the lower jaw in the region of the mental opening (mandibular-cortical index, MCI)



Fig. 4. Method of qualitative assessment of the type of cortical plate of the lower jaw

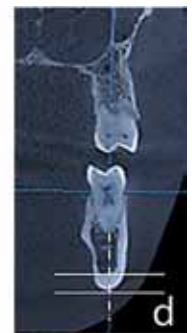
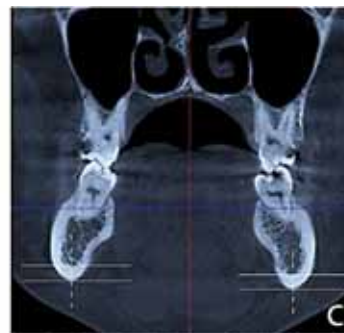
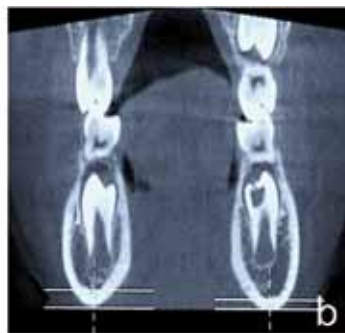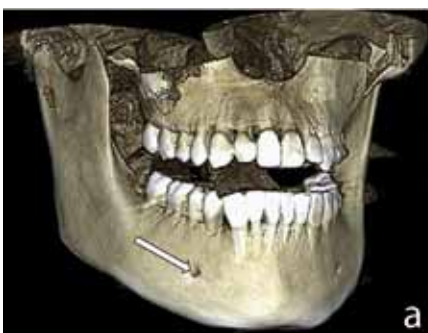Fig. 5. Cone-beam computed tomography in the region of premolars, angle of mandible (a). Determination of the thickness of the cortical layer on the frontal sections (b, c, d)

(free-standing, destroyed trabeculae), thinning of the cortical plates from the vestibular surface is observed (Fig. 7b). Evaluation of computer tomograms of the mandibular cross-sections of children with experience of type 1 diabetes from 5 to 10 years revealed the following violations of microarchitecture of the bone

tissue: destruction of the trabecular packet, multi-layer (stratification) of the cortical plate, the presence of thinned bone trabeculae not related to each other (Fig. 7c).

Systematizing the jaw bones X-ray data, we can state that increased bone resorption is most prominent

Table 1. The radiographic features of the jaw bone tissue status in the groups involved, (M±m)

Object of study	Research groups			
	Comparison group	First group	The second group	Third group
Fuchs index, (points)				
Upper jaw	1,0	0,83±0,03*	0,72±0,02*	0,64±0,05*
Lower jaw	1,0	0,92±0,04*	0,79±0,05*	0,71±0,04*
The averaged index	1,0	0,87±0,06*	0,75±0,07*	0,68±0,08*
X-ray index, (points)				
Upper jaw	0,0	0,02±0,01*	0,06±0,01*	1,13±0,02*
Lower jaw	0,0	0,05±0,01*	0,11±0,02*	1,16±0,01*
The averaged index	0,0	0,03±0,01*	0,08±0,01*	1,14±0,02*
Mandibular-cortical index, MCI, (mm)				
Lower jaw	3,8±0,3	3,7±0,1*	3,5±0,2*	3,4±0,1*
Frequency of occurrence of cortical plate types, (%)				
Lower jaw	C1 – 74,3 C2 – 25,7 C3 – 0	C1 – 57,6 C2 – 42,4 C3 – 0	C1 – 30,8 C2 – 53,8 C3 – 15,4	C1 – 23,8 C2 – 40,5 C3 – 35,7

Note: * – $p \leq 0,05$ is statistically significant in comparison with the parameters of patients in the comparison group.

Table 2. The radiological density of the mandibular body bone tissue in the groups under examination, (M±m)

Object of study	Research groups			
	Comparison group	First group	The second group	Third group
The mandibular body in the region of the 35 tooth, (Hounsfield units, HU)				
Average value, (M)	348,1	263,5*	39,2*	-126,7*
Standard deviation, (SD)	108,7	102,8*	127,4*	133,8*
Width of the window	71,0-669,0	37,0-422,0*	-83,0-198,0*	-271,0-23,0*
The angle of the lower jaw, (Hounsfield units, HU)				
Average value, (M)	736,4	539,1*	156,3*	5,6*
Standard deviation, (SD)	149,1	126,3*	71,8*	37,4*
Width of the window	372,0-1097,0	238,0-794,0*	106,0-429,0*	-46,0-73,0*
The thickness of the cortical layer of the lower jaw, (mm)				
	2,8±0,4	2,5±0,1**	2,1±0,2**	1,7±0,3**

Note: * – $p \leq 0,001$ is statistically significant in comparison with the patients of the comparison group; ** – $p \leq 0,005$ is statistically significant in comparison with the patients of the comparison group.

in children with a history of diabetes of type 1 exceeding 5 years, which has its course along with insufficient metabolic control, whereas the alveolar bone loss degree exceeds the similar values for the mandible in all the examined groups. An analysis of the qualitative indicators of the bone tissue (based on OPG and CBCT) in children of Group 3 points at the generalized nature of inflammatory-destructive changes that are manifested as a uniform decrease in the interalveolar septa height (within 1/3 of the root length); a widening periodontal gap; a density decrease and disturbed

microarchitectonics of the bone tissue in the jaws body (increased transparency of the bone substance, thinned bone trabeculae, restructured fiber arrangement, indistinctness, porosity, multilayered cortical plate all over, large-mesh pattern of the spongy bone).

Deteriorated periodontological status in children diagnosed with type 1 diabetes along with long-term chronic hyperglycemia results in disorganized morphology of the periodontium. Reduced compensation of endocrine pathology along with an increasing history of type 1 diabetes in children is combined with

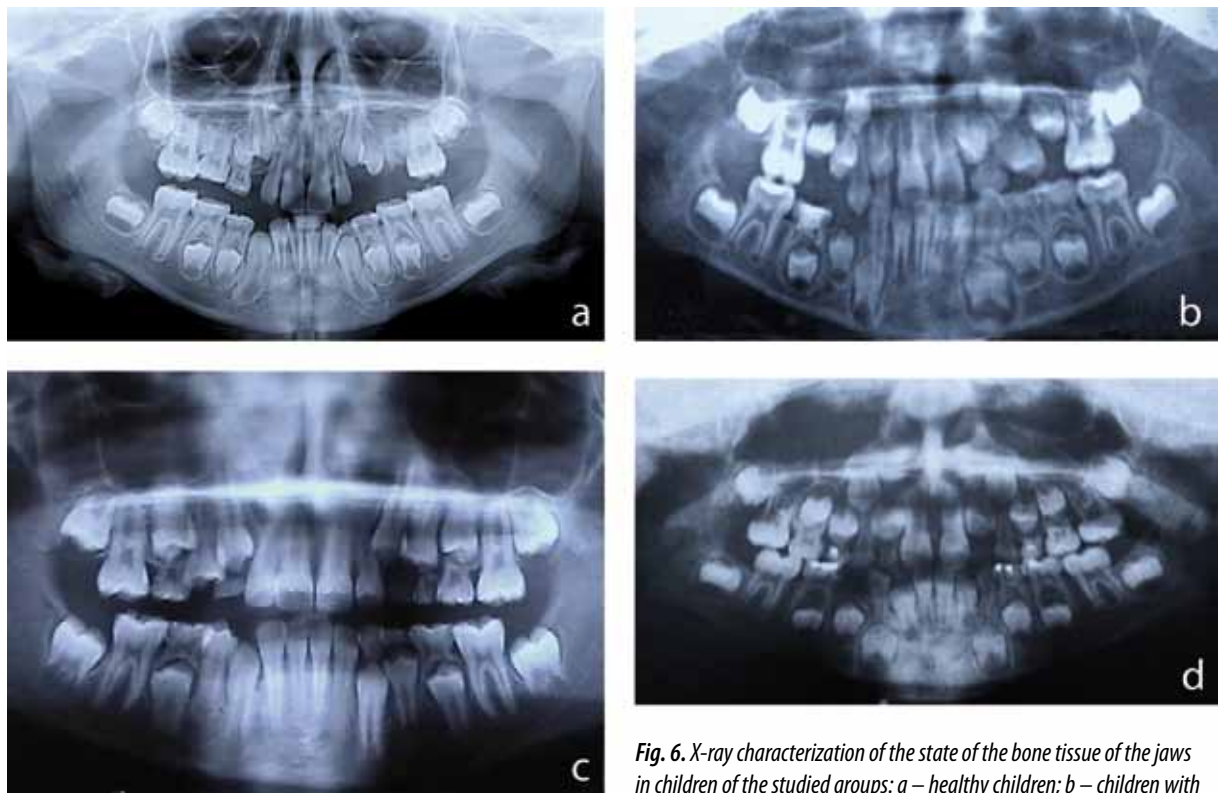


Fig. 6. X-ray characterization of the state of the bone tissue of the jaws in children of the studied groups: a – healthy children; b – children with experience of type 1 diabetes less than a year; c – children with the experience of type 1 diabetes from 1 year to 5 years; d – children with experience of type 1 diabetes from 5 to 10 years

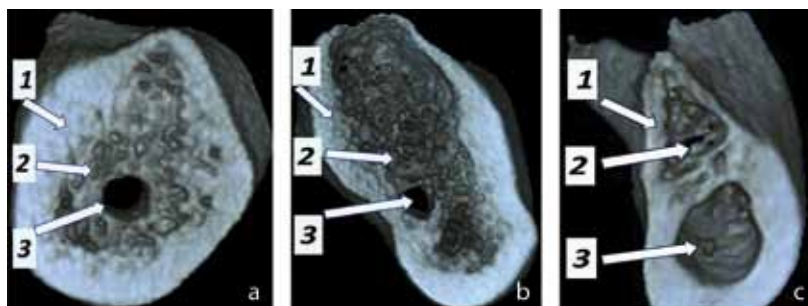


Fig. 7. Cone-beam computed tomography cross-section of the alveolar part of the mandible of a healthy child (a) and a child with experience of type 1 diabetes from 1 year to 5 years (b) and a child with experience of type 1 diabetes more than 5 years (c): 1 – cortical lamina, 2 – bone trabeculae, 3 – mandibular canal

intensified bone resorption and remodeling, progressing proteolytic degradation that correlates with uncontrolled destruction of the intercellular matrix, which manifests through disturbed barrier, protective, cushioning, trophic and plastic functions of the periodontal tissues. Experts have found that one of the most common bone tissue complications in case of diabetes mellitus is a decrease in the mineral density. Since there are no complaints reported regarding decreasing bone density in children with type 1 diabetes

(or as such issues may be difficult to define), identification of this parameter is an important criterion when diagnosing endocrinopathy and assessing the rate of bone complications development.

The results of studies focusing on the bone mineral density in the lumbar spine using the DXA method allowed identification of the following structure in the bone tissue: the patients of Group 1 – within the age norm 29 (87.9%) children; within the expected age norm – 4 (12.1%) children; Group 2 – within

age norm — 13 (33.3%) children; within the expected age norm — 17 (43.6%) children; low mineral density compared to the average age norm — 9 (23.1%); Group 3 — within the expected age norm — 24 (57.1%) children; low mineral density compared to the average age norm — 18 (42.9%) children. The recommendations adopted by the International Society for Clinical Densitometry (ISCD, 2005) say that children's (adolescents') increase in bone mass is mainly due to prominent bone mineralization against an increase in the growing body's skeleton size. Given this, the obtained BMD values are to be compared with the bone age, body length or put against the standards that allow calculating the Z-score mathematically in view of the age and body length. Interpretation of the skeleton bones densitometric parameters in children (adolescents) will take applying regional (population) databases (standards) calculated with a large sample pool and specific for a particular geographic area (population). The age, sex, ethnicity, race, genetics, hormonal background, health status and physical activity, as well as the nutrition, growth, etc. have been proven to have a significant influence on the bone mass increase. Our study used the pediatric reference database included in the Lunar iDXA densitometer software. Systematization of the obtained results allows stating that an increase in the history of type 1 diabetes in children comes along with a significant decrease in the bone mineral density (Z-score < -1SD), while the bone tissue structure reveals the prevalence of the criteria like *within the expected age norm and low mineral density compared to the average age norm*. A statistically significant decrease in the bone mineral density in children with a history of type 1 diabetes exceeding five years points, as we see it, at absolute insulin deficiency of pancreatic β -cells and an early debut of endocrine pathology during the bone tissue growth and development, which serves an impetus for osteopenic syndrome development.

Table 3 shows the calcium-phosphorus metabolism and the parameters of calcium-regulating hormones in the blood serum of the children within the studied groups.

The results of studying the serum phosphorus-calcium metabolism in children with type 1 diabetes revealed a bidirectional dynamic in view of the endocrinopathy history. In case of an increasing history of type 1 diabetes, the serum levels of total (Ca_{total}) and ionized calcium (Ca^{2+}) are below the reference values at normal levels of inorganic phosphorus (P) (i.e. within the physiological limits). An increasing history of type 1 diabetes comes along with an increase in the ratios of $\text{C}_{\text{total}}/\text{P}$ and Ca^{2+}/P , while the dependence of $\text{Ca}_{\text{total}}/\text{P}$ varies within the reference intervals,

and Ca^{2+}/P goes beyond the normative values, correlating with the severity of metabolic disturbances. The obtained outcomes are consistent with the data claiming that a decrease in the bone mineral density in children with type 1 diabetes features a compensatory increase in the intensity of bone development, which is confirmed by a progressive decrease in the blood levels of Ca^{2+} .

Wave-like fluctuations in the alkaline phosphatase levels (AP) within the normative values show that the earlier stages of endocrinopathy are associated with a growing rate of the bone tissue remodeling. The later stages of type 1 diabetes showed a decrease in the activity of AP, a marker of bone tissue development and a parameter for bone metabolism evaluation, which points at a decrease in the bone development intensity and gradual prevalence of bone resorption in the body.

Regulation of bone tissue remodeling is an extremely complex and multilevel process, while the most significant regulatory factors include parathyroid hormone, osteocalcin and calcitonin. Children with a type 1 diabetes history of up to one year have parathyroid hormone and calcitonin levels that are virtually no different from those of healthy children, which proves the intactness of the hormonal regulation mechanisms at earlier stages of the endocrinopathy. A sharp rise in the parathyroid hormone level in children with a history of type 1 diabetes from 1 to 5 years should be viewed as compensatory hyperparathyroidism, which helps maintain proper blood calcium levels through inhibiting calcium excretion in the urine and stimulating the osteoclasts activity. Besides, along with insulin deficiency and hypocalcemia, increased production of parathyroid hormone is one of the key factors in diabetic osteopenia pathogenesis. In children with a history of type 1 diabetes exceeding 5 years, a significant reduction in the parathyroid hormone content down to the reference values indicates an improper response of the calcium-regulating hormone to hypocalcemia. The calcitonin level, which is a functional parathyroid hormone antagonist, is within physiological values in children with a history of type 1 diabetes ranging from 1 to 5 years. A sharp increase in the calcitonin level in children with a history of type 1 diabetes beyond 5 years should be seen, on the one hand, as a compensatory response aimed at reducing bone resorption, while on the other — as a total result of discoordination in the mechanisms ensuring bone remodeling.

A prominent increase in the osteocalcin content (biochemical marker of bone development) in children whose history of type 1 diabetes falls in the groups of up to 1 year, and between 1 to 5 years, as we see it, points at an increased osteoblasts and

Table 3. The state of calcium-phosphorus metabolism and parameters of calcium-regulating hormones in blood serum in children of the study groups, ($M \pm m$)

Indicators, units of measurements	Reference intervals	Research groups			
		Comparison group	First group	The second group	Third group
Ca total, mmol/l	2,12-2,55	2,39±0,03	2,30±0,04*	2,21±0,02*	2,01±0,03*
Ca ++, mmol/l	1,12-1,32	1,23±0,02	1,17±0,02*	1,06±0,01*	0,98±0,02*
P, mmol/l	1,12-2,05	1,76±0,05	1,82±0,02*	1,68±0,04*	1,88±0,03*
Ca total / P	1/0,5-1/1,2	1/0,7	1/0,8	1/0,8	1/0,9
Ca ++ / P	1/1,10-1/1,50	1/1,43	1/1,56	1/1,58	1/1,92
The alkaline phosphatase, U/L	145,0-560,0	391,64±13,41	556,13±17,43*	302,75±9,81*	188,42±15,67*
Calcitonin, pg/ml	0,0-10,0	5,37±0,29	6,98±0,34*	3,63±0,47*	22,18±1,66*
Osteocalcin, ng/ml	2,80-41,00	30,38±2,96	104,51±7,26*	136,26±11,84*	24,27±1,68*
Parathyroid hormone, pg / ml	11,00-65,00	28,23±4,06	37,84±1,43*	69,07±3,51*	18,14±0,16*
25 OH vitamin D, nmol / l	27,70-107,00	47,63±1,84	35,06±2,38*	38,19±1,27*	29,34±1,91*

Note: * – $p \leq 0.05$ is statistically significant in comparison with the parameters of patients in the comparison group.

Table 4. The level of the C-terminal telopeptide of type I collagen in the serum of children in the study groups, ($M \pm m$), (ng / ml)

Reference intervals	Research groups			
	Comparison group	First group	The second group	Third group
0,101 - 0,580	0,106±0,03	0,187±0,026*	0,266±0,049*	0,127±0,014*

Note: * – $p \leq 0.05$ is statistically significant in comparison with the parameters of patients in the comparison group

odontoblasts metabolic activity, stimulation of bone mineralization, potentiation of histomorphometric rearrangement and the rate of the *young* bone development. A significant decrease in the osteocalcin level as a prognostic indicator of increased osteoporosis and demineralization in children with the endocrinopathy history beyond 5 years, reveals decreased bone development, predominance of bone resorption under *immature* bone development deficiency, and disturbed ossification (bone tissue development). A decrease in the content of 25 hydroxyvitamin D in children with type 1 diabetes along with an increasing history of the endocrinopathy within the reference intervals, stands proof to some *tension* in the mechanisms ensuring the calcium phosphoric and bone metabolism maintenance. A decrease in the 25 hydroxyvitamin D level down to the minimum threshold values potentiates the disturbance in the calcium absorption into the intestine, thereby increasing the parathyroid hormone level (secondary hyperparathyroidism) and the osteoclasts activity.

We believe that insulin deficiency is the main pathogenetic mechanism in the diabetic osteopathy

development and disturbed bone tissue metabolism in type 1 diabetes. Insulin has been proven to stimulate cell growth in different tissues, amino acid transport, protein biosynthesis, to have a direct stimulatory effect on collagen and hyaluronate synthesis, as well as an anabolic effect on bone tissue metabolism. Besides, insulin is involved in osteoblasts differentiation, prolongs the absorption of calcium and amino acids in the intestine, and enhances their incorporation into the bone tissue. Absolute insulin deficiency in case of type 1 diabetes will inhibit the osteoblasts activity, reduce collagen production by osteoblasts, which is necessary to develop the bone matrix and its mineralization, and potentiates metabolic acidosis, which increases the osteoclasts activity.

The results of biochemical studies focusing on bone metabolism markers in children with a history of type 1 diabetes exceeding 5 years have revealed, on the one hand, the dissociation of bone remodeling towards slower bone metabolism and, on the other, the predominance of resorption along with a decreasing bone development intensity. The range of the identified metabolic disorders observed at longer treatment

course of the endocrinopathy in children can be attributed to early manifestations of bone tissue damage.

Table 4 shows the level of collagen type I C-terminal telopeptide, as a marker of collagen type I degradation and disorganization of the extracellular matrix, in the blood serum of the children belonging to the groups within this study.

Progressive increase in the β -CrossLaps level, which correlates with an increase in the osteocalcin content in children with a history of type 1 diabetes of up to 1 year, and ranging within 1 to 5 years, indicates activation in the bone remodeling mechanisms with resorption predominance, increased degradation of interstitial type I collagen along with increasing clinical manifestations of the endocrinopathy as well as structural and functional destructive changes in insulin-producing β cells of the islets of Langerhans. A significant decrease in the β -CrossLaps level, accompanied with a decrease in the osteocalcin content in children with a history of the endocrine pathology above than 5 years, reveal the development of irreversible degenerative-dystrophic changes in the pancreas β -islet cells, a decrease in the extracellular matrix of active destruction, bone metabolism reduction, the predominance of resorption over bone development, as well as the *young* bone tissue development deficit combined with disturbed ossification.

CONCLUSIONS

1. The blood serum in children at their early stage of developing type 1 diabetes, features an increase in the ratio gradients of Ca_{total}/P and Ca^{2+}/P , the alkaline phosphatase activity, the levels of calcitonin, osteocalcin, parathormone, β -CrossLaps along with a decrease in the levels of calcium (total, ionized) and 25 hydroxyvitamin D, which points at an increase in the bone remodeling rate that correlates with an increase in the bone development intensity. The later stages of the endocrinopathy show a further increase in Ca_{total}/P and Ca^{2+}/P , the calcitonin level with decreasing calcium (total, ionized), the alkaline phosphatase activity, osteocalcin, parathyroid hormone and 25 hydroxyvitamin D, and β -CrossLaps, which is indicative of slowing bone remodeling with bone resorption predominance over bone development.

2. In children with type 1 diabetes, an increase in the endocrinopathy history has been registered to come along with a significant decrease in the bone mineral density (Z-score $< -1SD$), with bone tissue structure showing the prevalence of the criteria such as *within the expected age norm* and *low mineral density in relation to the average age norm*. A statistically significant decrease in the bone mineral density in children with a history of type 1 diabetes exceeding 5 years

indicates absolute insulin deficiency of the pancreatic β -cells, an early debut of endocrinopathy during the bone tissue growth and development, which is the impetus towards developing the osteopenic syndrome.

3. An increase in the history of type 1 diabetes in children involves a significant deterioration in the periodontological status, which is due to hormonal changes, disturbed salt-water exchange, and metabolic disorders. It is proven that as type 1 diabetes in children progresses, the bone tissue radiological density in the mandible angle decreases; the interalveolar septa height goes down and so does the mandible cortical layer width (thickness); there is also disturbed microarchitectonics of the bone tissue in the jaws body (bone substance increased transparency, thinned bone trabeculae, restructured fiber arrangement, indistinctness, porosity, multilayered cortical plate all over, large-mesh pattern of the spongy bone), while there is an increase in the share of children with insignificantly (type C2) or severely damaged (type C3) mandibular cortical layer.

4. The children diagnosed with type 1 diabetes, reveal disturbed bone metabolism at the later stages of the endocrinopathy, while such disturbance features a low level of bone metabolism, a decrease in the bone resorption activity and bone development, destruction of trabecular structure, a change in the extracellular matrix structure which is due to a disturbed balance between the bone proteins tissue synthesis and degradation, which involves the development of irreversible dystrophic changes. An increase in the history of type 1 diabetes, combined with poor metabolic control, increase the risk of developing not diabetic osteopenia alone yet also other specific diabetic complications.

REFERENCES

1. BYKOV I.M., IVCHENKO L.G., DOMENYUK D.A., KOSTYUKOVA N.Y., STOROZHUK A.P., ILIJEV D.M. Features of free radical oxidation and antioxidant protection in children with sugar diabetes of the first type. *Kuban Scientific Medical Bulletin*. 2017; (4): 27–38. (In Russ., English abstract). DOI: DOI:10.25207/1608-6228-2017-24-4-27-38.
2. BYKOV I.M., IVCHENKO L.G., DOMENYUK D.A., KOSTYUKOVA N.Y., STOROZHUK A.P., ILIJEV D.M. Salivary the level of proinflammatory cytokines in children with autoimmune diabetes mellitus in different phases of compensation endocrinopathy. *Kuban Scientific Medical Bulletin*. 2017; 24(4): 39–48. (In Russ., English abstract). DOI: 10.25207/1608-6228-2017-24-4-39-48.
3. DAVYDOV B.N., GILMIYAROVA F.N., DOMENYUK D.A., IVCHENKO L.G. Clinical and diagnostic significance of the activity of matrix metalloproteinase and their tissue inhibitors in assessing the condition of periodontal tissues in children with type 1 diabetes

- mellitus. Part I. Children's dentistry and prevention. 2017; Vol. XVI; 4 (63): 14–19. (In Russ.)].
4. **DAVYDOV B.N., GILMIYAROVA F.N., DOMENYUK D.A., IVCHENKO L.G.** Clinical and diagnostic significance of the activity of matrix metalloproteinase and their tissue inhibitors in assessing the condition of periodontal tissues in children with type 1 diabetes mellitus. Part II. Children's dentistry and prevention. 2018; Vol. XVII; 1 (64): 37–46. (In Russ.)].
 5. **DAVYDOV B.N., GILMIYAROVA F.N., DOMENYUK D.A., IVCHENKO L.G.** Optimization of diagnostics of type I diabetes in children according to the results of cytomorphological studies of buccal epithelium and processes of oxidative stress in the oral cavity. Children's dentistry and prevention. 2017; Vol. XVI; 3(62): 9–18. (In Russ.)].
 6. **DAVYDOV B.N., VEDESHINA E.G., DMITRIENKO S.V., DOMENYUK D.A.** Radiological and morphometric methods for comprehensive assessment of cephalo-odontologic status in dental patients (Part I). The Dental Institute. 2017; 75(2):58–61. (In Russ.)].
 7. **DAVYDOV B.N., VEDESHINA E.G., DMITRIENKO S.V., DOMENYUK D.A.** Radiological and morphometric methods for comprehensive assessment of cephalo-odontologic status in dental patients (Part II). The Dental Institute. 2017; 76(3): 32–35. (In Russ.)].
 8. **DOMENYUK D.A., DAVYDOV B.N., GILMIYAROVA F.N., IVCHENKO L.G., VEDESHINA E.G.** Diagnostic and prognostic value of crystalline structures of the oral fluid in children with anomalies of occlusion. Children's dentistry and prevention. 2017; Tom XXI; 2(61): 9–16. (In Russ.)].
 9. **DOMENYUK D.A., TASHUEVA L.V., ZELENSKY V.A., IVANCHEVA E.N.** Evaluation of microvasculature tissues viability after the imposition of removable orthodontic appliances in children and adolescents // *Archiv EuroMedica*, 2013. – Vol. 3. – № 1. – P. C. 5–9.
 10. **DOMENYUK D., PORFYRIADIS M., DMITRIENKO S.** Major telerehthengogram indicators in people with various growth types of facial area // *Archiv EuroMedica*, 2018. – T. 8. – № 1. – C. 19–24.
 11. **DOMENYUK D.A., DAVYDOV B.N., VEDESHINA E.G., DMITRIENKO S.V.** Perfection of diagnostic methods of dentoalveolar anomalies by results of studying functional shifts in the system of oral homeostasis (Part I). The Dental Institute. 2016; 71(2): 74–77. (In Russ.)].
 12. **DOMENYUK D.A., DAVYDOV B.N., VEDESHINA E.G., DMITRIENKO S.V.** Perfection of diagnostic methods of dentoalveolar anomalies by results of studying functional shifts in the system of oral homeostasis (Part II). The Dental Institute. 2016; 72(3): 58–60. (In Russ.)].
 13. **DOMENYUK, D.A.** Study of the spectrum of dental composites biological activity in model experiments in vitro / D.A. Domyuk, E.G. Vedeshina, V.A. Zelensky, K.G. Karakov, M.P. Porfiriadis, I.A. Bazikov, F. N. Gilmiyarova // *Medical news of North Caucasus*. 2016. – Vol. 11. – № 2. – P. 179–183. (In Russ.) DOI: 10.14300/mnnc.2016.11031.
 14. **DOMENYUK, D.A.** Semiquantitative evaluation of caries microflora in patients with dental and alveolar abnormalities and different severity of morphofunctional disturbances / D.A. Domyuk, E.G. Vedeshina, V.A. Zelensky, K.G. Karakov, M.P. Porfiriadis // *Medical news of North Caucasus*. 2015. – Vol. 10. – № 3. – P. 238–241. (In Russ.) DOI: 10.14300/mnnc.2015.10055.
 15. **DOMENYUK D.A., DAVYDOV B.N., DMITRIENKO S.V., LEPILIN A.V., FOMIN I.V.** Study of morphology, methods of comparison of tooth and alveolar arcs by results of anthropometry and cellular-beam computer tomography (Part I). The Dental Institute. 2018; 79(2): 68–72. (In Russ.)].
 16. **DOMENYUK D.A., GILMIYAROVA F.N., VEDESHINA E.G., IVCHENKO L.G.** The diagnostic significance of the clinical functional and immunological studies in assessing the effectiveness of complex therapy of chronic gingivitis (Part I). The Dental Institute. 2017; 74(1): 46–47. (In Russ.)].
 17. **DOMENYUK D.A., GILMIYAROVA F.N., VEDESHINA E.G., IVCHENKO L.G.** The diagnostic significance of the clinical functional and immunological studies in assessing the effectiveness of complex therapy of chronic gingivitis (Part II). The Dental Institute. 2017; 75(2): 30–33. (In Russ.)].
 18. **DOMENYUK D.A., VEDESHINA E.G., DMITRIENKO S.V.** Teeth sizes in their correlation with parameters of dentofacial arches and maxillofacial area based on native cranial preparations examination. *Kubanskij nauchnyj medicinskij vestnik*. 2016;(2):71–79. (In Russ.) DOI:10.25207/1608-6228-2016-2-71-79.
 19. **DOMENYUK D.A., VEDESHINA E.G., DMITRIENKO S.V.** The use of craniometric and morphological studies in the assessment of structural elements of the temporomandibular joint. *Kubanskij nauchnyj medicinskij vestnik*. 2017;1(1):33–40. (In Russ.) DOI:10.25207/1608-6228-2017-1-33-40.
 20. **DOMENYUK D.A., DAVYDOV B.N., DMITRIENKO S.V., PORFYRIADIS M.P., BUDAYCHIEV G.M.-A.** Variability of cephalometric indices in men and women with mesocephalic form of the head and various constitutional types of face (Part I). The Dental Institute. 2018; 78(1): 70–73. (In Russ.)].
 21. **DOMENYUK D.A., DAVYDOV B.N., DMITRIENKO S.V., PORFYRIADIS M.P., BUDAYCHIEV G.M.-A.** Variability of cephalometric indices in men and women with mesocephalic form of the head and various constitutional types of face (Part II). The Dental Institute. 2018; 79(2): 82–85. (In Russ.)].
 22. **GILMIYAROVA F.N., DAVYDOV B.N., DOMENYUK D.A., IVCHENKO L.G.** Influence of severity of type I diabetes mellitus in children on dental status and immunological, biochemical parameters of blood serum and oral fluid. Part I. *Periodontology*. 2017; Vol. XXII; 2 (83): 53–60. (In Russ.)].
 23. **GILMIYAROVA F.N., DAVYDOV B.N., DOMENYUK D.A., IVCHENKO L.G.** Influence of severity of type I diabetes mellitus in children on dental status and im-

- munological, biochemical parameters of blood serum and oral fluid. Part II. Periodontology. 2017; Vol. XXII; 3 (84): 36–41. (In Russ.).
24. **IVCHENKO L.G., DOMENYUK D.A.** Diagnosis of immunometabolic disorders in children with type I diabetes mellitus. *Kuban Scientific Medical Bulletin*. 2017; 1(2): 73–82. (In Russ., English abstract). DOI:10.25207/1608-6228-2017-2-73-82.
 25. **KARSLIEVA A.G., DOMENYUK D.A., ZELENSKY V.A.** Mixed saliva trace element composition in children with dentoalveolar anomalies through apparatus-involved treatment // *Archiv EuroMedica*, 2014. – Vol. 4. – № 1. – P. 29–35.
 26. **KOROBKEEV, A.A.** Changes in the structural elements of the temporomandibular joint with distal occlusion / A.A. Korobkeev, D.A. Domenyuk, E.G. Vedeshina, V.V. Konov, O.Yu. Lezhnina, Ya.A. Korobkeeva // *Medical news of North Caucasus*. 2017. – Vol. 12. – № 1. – P. 72–76. (In Russ., English abstract). DOI: 10.14300/mnnc.2017.12020.
 27. **KULIKOVA, N.G.** Evaluation of the effectiveness of pharmacophysiotherapeutic treatment of catarrhal gingivitis on the results of the condition of mucosal immunity of oral cavity in women in the postpartum period / N.G. Kulikova D.A. Domenyuk, V.A. Zelensky, A.S. Tkachenko // *Medical news of North Caucasus*. 2017. – Vol. 12. – № 4. – P. 417–421. (In Russ., English abstract). DOI: 10.14300/mnnc.2017.12117.
 28. **LEPILIN A.V., FOMIN I.V., DOMENYUK D.A., DMITRIENKO S.V.** Diagnostic value of cephalometric parameters at graphic reproduction of tooth dental arches in primary teeth occlusion // *Archiv EuroMedica*, 2018. – T. 8. – № 1. – C. 37–38.
 29. **PORFYRIADIS M.P., VEDESHINA E.G., DMITRIENKO S.V., DOMENYUK D.A., DAVYDOV B.N.** Features of tactics and principles orthodontic treatment of patients with dental arches asymmetry caused by different amounts of antimeres (Part I). *The Dental Institute*. 2017; 77(4): 64–68. (In Russ.).
 30. **PORFYRIADIS M.P., VEDESHINA E.G., DMITRIENKO S.V., DOMENYUK D.A., DAVYDOV B.N.** Features of tactics and principles orthodontic treatment of patients with dental arches asymmetry caused by different amounts of antimeres (Part II). *The Dental Institute*. 2018; 78(1): 56–61. (In Russ.).
 31. **PORFYRIADIS M.P., VEDESHINA E.G., DMITRIENKO S.V., DOMENYUK D.A., DAVYDOV B.N.** Features of tactics and principles orthodontic treatment of patients with dental arches asymmetry caused by different amounts of antimeres (Part III). *The Dental Institute*. 2018; 79(2): 88–92. (In Russ.).
 32. **SHKARIN V.V., DOMENYUK D.A., DMITRIENKO S.V., PORFYRIADIS M.P., FOMIN I.V.** Modern approaches to the determination of the angle of teeth inclination in the diagnosis and planning of orthodontic treatment. *Kuban Scientific Medical Bulletin*. 2018; 25(2): 156–165. (In Russ., English abstract). DOI: 10.25207 / 1608-6228-2018-25-2-156-165.
 33. **SHKARIN V., DOMENYUK D., LEPILIN A., FOMIN I., DMITRIENKO S.** Odontometric indices fluctuation in people with physiological occlusion // *Archiv EuroMedica*, 2018. – T. 8. – № 1. – C. 12–18.
 34. **VEDESHINA E.G., DOMENYUK D.A.** Buccal epithelium reactivity indicators as markers of morphological and functional impairment in patients with dentoalveolar pathology. *Kuban Scientific Medical Bulletin*. 2016; (4): 23–32. (In Russ., English abstract). DOI:10.25207/1608-6228-2016-4-23-32.
 35. **ZELENSKY, V.A.** Integral indicator for orthodontic carequality control / V.A. Zelensky, D.A. Domenyuk, M.V. Baturin, I.V. Zelensky, A.V. Kokareva, A.V. Zenina // *Medical news of North Caucasus*. 2014. – Vol. 9. – № 1. – P. 80–83. (In Russ., English abstract). DOI: 10.14300/mnnc.2014.09022.

The authors declare no conflict of interest