

## MODELING OF THE IMPLANT FOR VENTRAL HERNIAS

*I.O. Kalyakanova, A.V. Protasov,  
Z.S. Kaitova, A.L. Kulakova*

*Department of operative surgery and clinical anatomy by I.D. Kirpatovsky,  
RUDN University, Moscow, Russia*

### **Correspondence address:**

*Department of operative surgery and clinical anatomy by I.D. Kirpatovsky,  
RUDN University, Moscow, Russia. E-mail: paramonova-irina91@mail.ru*

**ABSTRACT** — The issue associated with hernioplasty of ventral hernias does not cease to be relevant. And even the opposite with the development of technologies and new materials for implantation, there are more and more questions, which one to choose. Our study included the ProGrip™ self-gripping implant, which showed good biocompatibility properties and was also convenient to use. However, the long-term results of treatment were not satisfactory due to relapse. In this regard, a simulated implant was developed and implemented in practice.

**KEYWORDS** — postoperative ventral hernia, material for implants.

### THE RELEVANCE OF RESEARCH

One of the first, and most common, surgical pathologies where alloplastic materials for prosthetics began to be used are hernias. Surgery for hernia of the anterior abdominal wall was initially crippling and with high mortality, therefore, in many countries of the ancient world, hernia repair was prohibited. A new stage using prosthetics began in the early twentieth century with the help of implants made of silver, gold, various metals.

But in the postoperative period, the use of implants from these materials caused severe complications. After World War 2, research began on the possibility of using polymeric synthetic materials in medicine. One of the first in 1959 F.C. Usher proposed the use of polypropylene for medical purposes [1, 2, 3]. The use of mesh implants, although reduced the risk of recurrence of the hernia, however, up to 30% of patients again seek surgical help. Therefore, the question of choosing a mesh implant and the method of its application remains open [4].

In the process of research it was proved that the implant of the cellular structure, better than monolithic or perforated, which was used initially. Through the cellular structure, connective tissue grows faster, form-

ing the skeleton of the anterior abdominal wall, from the formation of which depends on the development of relapse in the future. The duration and quality of the ingrowth of the prosthesis into the surrounding tissues are influenced by both the physical properties of the prosthesis, such as the size and shape of the pores, the specific weight, density and structure of the material used, and the characteristics of the human body [5].

The formation of a connective tissue scar depends on the collagen metabolism at different stages of the wound process, with a change in the ratio of the amount of collagen I and type III [6, 7].

Formed frame, consisting of an implant and connective tissue, should ensure the strength and elasticity of the anterior abdominal wall. In accordance with this, the requirements for “ideal” implants were formulated, one of which is biocompatibility, which includes the absence of allergic reactions, sensitization, inflammation and rejection. The materials from which the implants are made must retain elastic properties throughout the lifetime, physical and chemical properties after sterilization, and should not be toxic and carcinogenic to humans [8, 9].

### *Currently, hernioplasty uses implants of three main materials:*

1. Polytetrafluoroethylene (PTFE) — microporous material, the pore size is 10 microns, which ensures flexibility and elasticity. But at the same time, microporosity impairs the ingrowth of the mesh into the surrounding tissues and encapsulation occurs. As a result of the encapsulation, the elastic properties are lost, as well as the displacement of the mesh prosthesis. Therefore, these types of implants are almost not used [8, 10].

2. Polypropylene (PP) — light macroporous consisting of monofilament. This type of implant is well integrated into the surrounding soft tissue, thanks to the size of pores, the penetration of macrophages, vessels and fibroblasts is not difficult. However, a thin connective tissue capsule is again formed around the prosthesis, forming a rough scar with imperfect implant growth. And the processes of degradation of the material cause a loss of physical properties.

The reduction of the prosthesis occurs up to 50% of the original size with a displacement of the implant, which can lead to a recurrence of the hernia. A number of studies have established that the severity of the inflammatory reaction and the activity of fibrosis in the implantation zone directly depend on the amount of polypropylene [11, 12, 13].

3. Polyester (PE) — is a light and elastic macroporous material using a special type of multi-thread weaving. Due to this structure, good germination of connective tissue is ensured and does not cause inflammatory reactions [14, 15].

Recently, composite mesh implants have appeared, using two-component materials with a hydrolyzing component and a reduced amount of polypropylene, teflon or polyester. Such implants can be used for intra-abdominal plastics, as additional coatings are used that do not cause adhesion and the formation of adhesions of the abdominal organs with an implant [16].

Composite implants can also include self-locking mesh prostheses, which are fixed to the tissues with the help of adhesive coatings or micro-hooks, which dissolve over time [17]

Covidien's Progrid implant has shown good results with few neuralgia, inflammatory reactions and recurrences in the postoperative period. The advantages of this implant is that it is self-gripping, due to micro-hooks from polylactic acid, which dissolve within 15 months after the operation, while for the ingrowth of the grid it is necessary 2-4 months. Micro-hooks provide reliable fixation of the mesh and distribute the load evenly over the entire surface of the mesh, unlike suture fixation [18, 19, 20, 21].

Thus, the goal of our study was to determine the effectiveness of the use of the Progrid™ self-gripping implant.

#### *Materials and methods.*

The study included 66 patients operated on for postoperative ventral hernia. The first group of patients consisted of persons up to 60 years old, the second group includes patients older than 60 years old (Table 1). In each group, patients were operated on using a standard-shaped Progrid™ self-gripping implant (subgroup B) and a modeled one (subgroup A).

Self-gripping implant was used since the fixation of the implant occurs evenly in contrast to the implants which need to be fixed to the tissues with additional material around the perimeter. When changing the shape of the implant, the physical tension of the muscles of the anterior abdominal wall was taken into account.

The implant of the standard form — oval, removes the transverse load from the aponeurosis of the rectus abdominis muscles due to fixation of the rectus muscles to the back wall of the vagina and compensation of the tensile force working on the seam rupture, distributing it unevenly. Within the boundaries of the rectus abdominis muscles, the standard implant stops compensating for the stretching force, making the muscle-aponeurotic tissues not expandable.

And the fixation points A1, A2, B1 and B2 are at the same time the points of application of tensile transverse forces and forces directed from the inside of the abdominal cavity, which leads to tearing of the tissue in a given area or tearing the implant. In the modified implant, there is a cut on the opposite sides of the implant along the longitudinal axis, due to which only the longitudinal load remains, and the lack of transverse stretching force reduces the load at points D1 and D2. This prevents tissue rupture and implant detachment, and consequently reduces the risk of recurrence (Fig. 1.).

According to the Chevrel J.P. and Rath A.M. (1999), the study included patients SmW1-4R0-2 where "Sm" means the median localization. Patients with mixed and lateral localization of the defect were excluded since it is impossible to use the simulated implant under this localization. The width of the hernial defect — "W" and the number of relapses — "R" did not matter in the selection of patients. The width of the hernial ring varied from 4 to 25 cm. The most frequent were patients with the size of the hernia gate W3 (10-15 cm) — 23 people (34.8%).

In terms of the number of relapses there were patients both after midline laparotomies and undergoing surgical interventions for postoperative hernia, including alloplasty. Recurrent hernias were present in 21 (31.8%) patients, in other cases hernioplasty was performed for the first time.

The primary defect of the anterior abdominal wall was formed as a result of planned and emergency surgical interventions. The most frequent operations were hernia of the anterior abdominal wall (white hernia of the abdomen, umbilical hernia, ventral hernia) — 10 people (15.2%), which later became postoperative ventral hernias reaching the size of the hernia gate 25 cm.

The period of treatment of patients for help from the onset of the hernial defect varied greatly and ranged from 6 months to 10 years. During the year only 23 people asked for help (34.8%), which once again confirms the medical illiteracy of patients and careless treatment of their health.

The volume of the examinations carried out in the preoperative period met all the requirements of preparation for chronic diseases, if necessary additional examinations were prescribed in the form of ultrasound examination (USI) of the abdominal organs and kidneys, vessels (veins and arteries) and heart; spirometry, radiography, computer tomography. The risk assessment of the development of venous thromboembolic complications (VTEC) was also carried out on the Caprini scale.

In the postoperative period all patients received adequate analgesia on the first day after surgery;

Table 1. The distribution of patients in groups

	1st group	2d group	Total
Modeled (simulated) implant	14	17	31
Standard implant	18	17	35
Total	32	34	66

currence was recorded in 6 (9.1%) patients. However, only one patient under 60 years of age had a relapse with a simulated implant, the cause of the recurrence was the failure to follow the clinical guidelines in the first 6 months after the surgery. In the remaining 5 (7.5%) cases no reliable data on the cause of the relapse was obtained (Table 2).

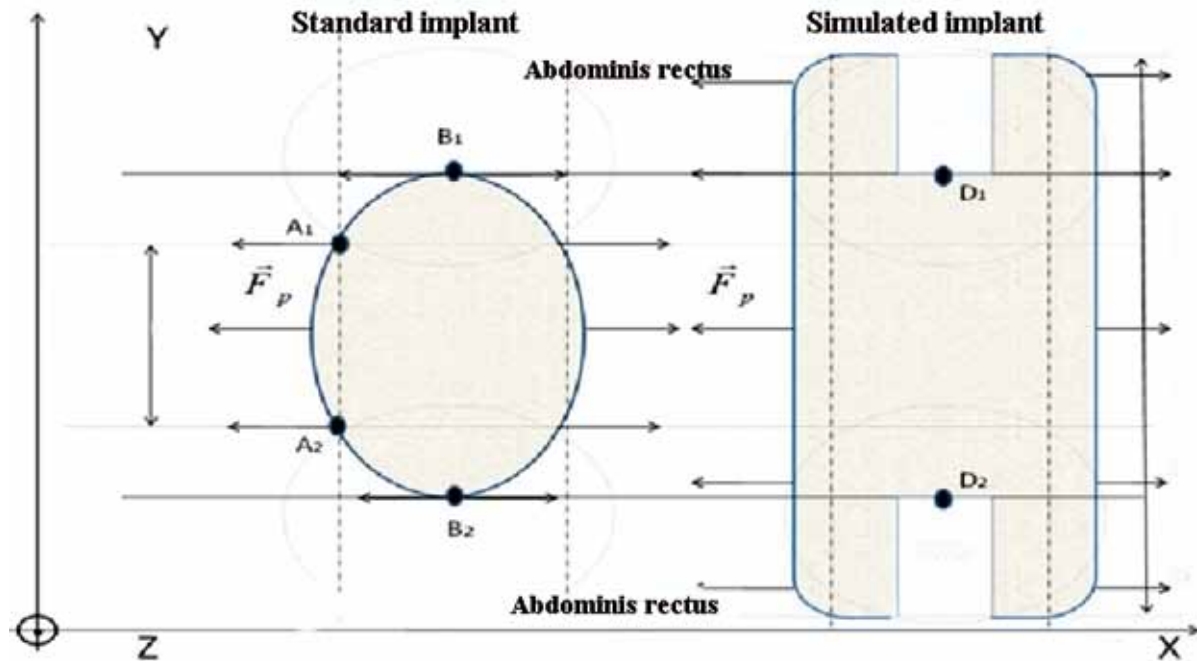


Fig. 1. Simulated and standard implants

further analgesia was performed according to indications. If necessary, antibiotic therapy and prevention of thromboembolic complications were prescribed. Used tactics of early activation of patients using a bandage.

In the postoperative period all patients received adequate analgesia on the first day after surgery; further analgesia was not according to indications. If necessary antibiotic therapy and thromboembolic complications were prescribed, same tactics on patients with the bandage.

In the immediate postoperative period postoperative wound suppuration occurred in patients with a history of secondary wound healing after surgery despite the ongoing massive antibiotic therapy and daily wound dressings. Complications associated with the formation of seroma and suppurative hematoma were also conservatively resolved; no additional surgery was required (Table 2).

In the late postoperative period the follow-up period for patients was from 2 to 8 years. Disease re-

Table 2. Complications in the early and late postoperative period

	1st group		2d group		Total
	A	B	A	B	
Postoperative wound suppuration	0	1	0	1	2
Suppurative hematoma	0	1	0	0	1
Seroma	1	0	1	0	2
Foreign body sensation	0	0	0	2	2
Relapse	1	2	0	3	6

Despite of the volume of performed examinations it was impossible to avoid the complications of chronic diseases completely. Even with the condition of early activation of patients on the 6<sup>th</sup> day after hernioplasty, one patient in the 2<sup>nd</sup> group experienced acute intestinal obstruction associated with adhesions in the abdominal cavity. On the background of the ongoing conservative therapy positive dynamics were useless. The patient underwent surgery in the volume

of laparotomy, adhesions dissection, nasointestinal intestinal intubation. The implant was retained during surgery. Further postoperative period showed no interest.

## CONCLUSION

The simulated (modeled) implant shows good results of treatment in the long term in both young and old patients, its introduction and use in a wide surgical practice can be recommended for postoperative ventral hernias of the middle localization.

## REFERENCES

1. **ZAGDOUN J.**: L'utilisation des plaques de nylon dans la chirurgie des hernies inguinales. *Mem Acad Chir.* 1959. P. 747–753
2. **AMID PK, LICHTENSTEIN IL, SHULMAN AG, HAKAKHA M.** Minerva Biomaterials for "tension-free" hernioplasties and principles of their applications. *Chir.* 1995. 50 (9): 821–6.
3. **PROTASOV A.V., BOGDANOV D.YU., MAGOMADOV R.K.** Practical aspects of modern hernioplasty. M.: RUSAKI. 2011. C.6–31
4. **POULOSE B.K., SHELTON J., PHILLIPS S., ET AL..** Epidemiology and cost of ventral hernia repair: making the case for hernia research. *Hernia.* 2012. 2: 179–183
5. **PROCTER L., FALCO E.E., FISHER J.P., ROTH J.S.** Abdominal wall hernias and biomaterials: Bioengineering research of chronic wounds. 1st ed. Berlin Heidelberg: Springer Verlag. 2009. P. 425–447
6. **LAZARENKO V.A., IVANOV I.S., TSUKANOV A.V., IVANOV A.V., GORYAINOVA G.N., OBEDKOV E.G., TARABRIN D.V., GAFAROV G.N.** Architectonics collagen fibers in the skin and aponeurosis in patients with ventral hernias and without hernial disease. *Kursk scientific and practical bulletin "Man and his health."* 2014. 2: 41–45.
7. **SLAVIN L. YE., CHUGUNOV A. N., BORISOVA I. YU., SHAKIROVA A.Z., ALIULLOVA R. R.** Features of connective tissue affecting the results of surgical treatment of abdominal hernias. *Kazan Medical Journal.* 2013. 1 (94): 86–89
8. **SOVTSOV SA, PRYAKHIN A.N., SHESTOPALOVA I.S.** Main principles and materials for prosthetic plastics of external abdominal hernias. Chelyabinsk: study guide. 2009. P. 12–25
9. **BILSEL Y., ABCI I.** The search for ideal hernia repair: mesh materials and types. *International Journal of Surgery.* 2012. 10: 317–321
10. **SABERSKI E.R., ORENSTEIN S.B., NOVITSKY Y.W.** Anisotropic evaluation of synthetic surgical meshes. *Hernia.* 2011. 15: 47–52
11. **KALMIN OV, NIKOLSKY V.I., FEDOROVA M.G., TITOVA E.V., YANGURAZOVA E.V.** Morphological changes of tissues in the area of operation during the implantation of xenopericardium and polypropylene mesh at different times after surgery. *Saratov Scientific Medical Journal.* 2012. 4: 1008–1012
12. **BACHMAN S., RAMSHAW B.** Prosthetic material in ventral hernia repair: how do I choose? *Surgery Clinic.* 2008. 88: 101–112
13. **TOBIAS A.M., LOW D.W.** The use of subfascial vicryl mesh buttress to aid in the closure of massive ventral hernias following damage-control laparotomy. *Plastic and reconstructive surgery.* 2009. 3. (112): 766–776
14. **MIKHIN I.V., KUKHTENKO, YU.V., PANCHISHKIN A.S.** Large and giant postoperative ventral hernia: the possibilities of surgical treatment (literature review). *Bulletin of the Volgograd State Medical University.* 2014. 2 (50): 8–16.
15. **GABOYAN A.S., KLIMOV A.E.** Non-tension methods of plastics hernia of the abdomen using modern allografts. M.: 2008. P. 21
16. **BROWN C.N., FINCH JG.** Which mesh for hernia repair?. *About annals of the royal college of surgeons of England.* 2010. 92: 272–278
17. **VORST A.L., KAOUTZANIS C., CARBONELL A.M., FRANZ M.G.** Evolution and advances in laparoscopic ventral and incisional hernia repair. *J. Gastrointestinal surgery.* 2015. 7 (11): 293–305.
18. **SMIRNOVA, E.D., PROTASOV, A.V., SHUKHTIN, N.YU., TITAROV, D.L., NAVID, M.N.** Allogeneoplasty using a non-latching implant. *News of Tula State University. Natural Sciences.* 2011. 1: 265–272.
19. **I. HOPSON S.B., MILLER L.E.** Open ventral hernia repair using ProGrip™ self-gripping mesh. *International J. of Surgery.* 2015. 23 (A): 137–140
20. **16. VERHELDS J, GOEDE B., KLEINRENSINK G.J., JEEKEL J. ET AL.** Open incisional hernia repair with a self-gripping retromuscular Parietex mesh: A retrospective cohort study. *International journal of surgery.* 2015. 13: 184–188
21. **WANG Y., ZHANG X** Short-term results of open inguinal hernia repair with self-gripping Parietex Pro-Grip mesh in China: A retrospective study of 90 cases. *Asian journal of surgery.* 2016. 4 (39): 218–224