

<http://dx.doi.org/10.35630/2199-885X/2020/10/3.11>

# MAGNETIC RESONANCE AND ULTRASOUND IMAGING: DO THE LINEAR LIVER MEASUREMENTS DIFFER IN MEN AND WOMEN?

Received 7 July 2020;  
Received in revised form 18 August 2020;  
Accepted 21 August 2020

Irina Stepanyan<sup>1,2✉</sup> , Vladimir Izranov<sup>1</sup> ,  
Valentina Gordova<sup>1</sup> , Rodion Rohwein<sup>3</sup> ,  
Stepan Stepanyan<sup>1</sup> 

<sup>1</sup> Immanuel Kant Baltic Federal University, Kaliningrad,

<sup>2</sup> Infectious Diseases Hospital of the Kaliningrad region, Kaliningrad,

<sup>3</sup> Children's Regional Hospital of the Kaliningrad region, Kaliningrad, Russia

✉ [lublumedcinu@mail.ru](mailto:lublumedcinu@mail.ru)

**ABSTRACT** — Magnetic resonance and ultrasound measurements of the liver were performed and compared in 58 adult healthy volunteers (26 men и 32 women). The aim of this study was to distinguish differences in linear liver measurements between men and women. Statistically significant gender differences were found in the following liver diameters: anteroposterior diameter of the left lobe, thickness of the caudate lobe, anteroposterior and oblique maximum craniocaudal diameters of the right lobe. In men all these diameters are larger than in women.

**KEYWORDS** — magnetic resonance imaging, ultrasound imaging, linear measurements of the liver, men and women, gender differences.

## INTRODUCTION

Knowledge of the liver size is an important factor in the diagnosis of wide range of pathologies and one of the most significant criteria for determining its condition. Far back as 1983 Dittrich M. et al. [1] informed that evaluation of liver's sizes by palpation and percussion is unreliable and suggested ultrasound morphometry which can be used successfully to determine the liver size as well as to detect partial enlargement of organ. In 2010 Silva R.M. et al. [2] showed that liver measurements obtained by clinical examination correlates well with ultrasound method, but underestimated the actual liver size in adults, which can be demonstrated by the statistically significant difference between the final mean value obtained by clinical observation and that obtained by ultrasound method. A 2013 study of Mouratev et al. [3] demonstrated that medical students with less than two hours training

could obtain liver size measurements using ultrasound that were more accurate and had less variability than physicians with 10 to 20 years of clinical experience) using physical examination, including palpation, percussion and auscultation scratch techniques.

Computed tomography (CT) and magnetic resonance imaging (MRI) are regarded as a gold standard to determine liver size and volume. However, both methods have contraindications and CT/MRI equipment are very expensive and not mobile. Moreover, CT brings the risk of ionising radiation.

Thus, ultrasound (US) is currently considered to be the first tool of visualization technique after clinical suspicion of hepatomegaly [4] due to numerous advantages, including availability of ultrasound devices in most medical institutions, as well as mobile devices; safe (absence of contraindications and the risk of ionising radiation), inexpensive, provides rapid results and the possibility of repeatedly ultrasonography examination for dynamic monitoring.

Body composition differs between men and women [5]. In relation to liver size it depends on several factors: age, sex, body size and shape, as well as the particular examination technique utilized (physical examination versus radiographic) [6]. We were interested if the definite liver measurements differs in men and women.

### *The aim of this study*

is comparing linear liver's measurements in men and women performed by magnetic resonance and ultrasound imaging.

## MATERIALS AND METHODS

In 58 adult healthy volunteers (26 men и 32 women) in MRI and US of abdominal organs were carried out linear liver's measurements. In left lobe were measured: craniocaudal diameter (CC, length), anteroposterior diameter (AP, depth) and thickness of the caudate lobe (CL). In right lobe were measured: craniocaudal diameter (CC, length), anteroposterior (AP) and oblique maximum craniocaudal (OCC max) diameters. Right lobe measurements were performed in the right midclavicular line (MCL) and

in the right anterior axillary line (AAL). All measurements of liver were taken at the widest points. To exclude changes in the liver sizes over the time MRI and US were performed in one day (all participants were fasting before examinations).

Ultrasound liver measurements were performed with convex transducers using Aixplorer (SuperSonic Imagine, France) and SonoScapeS6 (China) ultrasound systems. All volunteers were investigated in the supine position with the both arms placed above the head, the stretched legs and with quiet breathing.

Magnetic resonance imaging (MRI) were performed on the MRI System GE Optima MR 450w 1.5T 70 cm. MRI measurements were performed according to the generally accepted method of ultrasound diagnostics (fig. 1, fig. 2)

Determination of liver linear diameters obtained on MRI was performed on iMac 27 Retina 5K using Osirix DICOM Viewer software. We compared liver linear diameters, obtained on MRI with linear diameters obtained on US.

All data were analyzed using the Statistical Package for the Social Sciences (SPSS) software recommended for analysis of biomedical data. For each parameter studied, the average values and standard error of the mean were calculated. The significance of differences in the mean values of independent samples was evaluated using the nonparametric Mann-Whitney test, p-values of less than 0.05 were considered statistically significant.

## RESULTS AND DISCUSSION

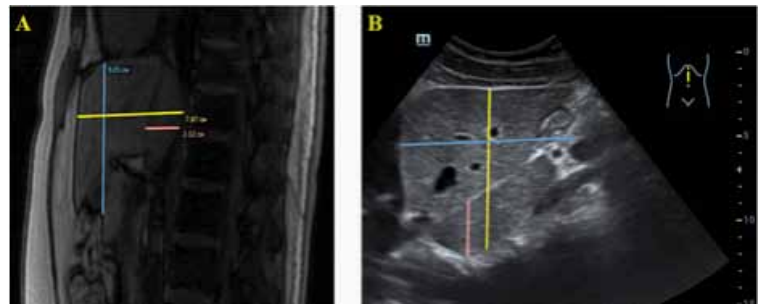
Results of liver examination in healthy volunteers performed by MRI and US are shown in Tables 1 and 2.

The table 1 shows us that all linear diameters of the left liver lobe obtained by MRI are similar with the same diameters by US, except for one. In women AP diameter using US on average by 9% less than MRI.

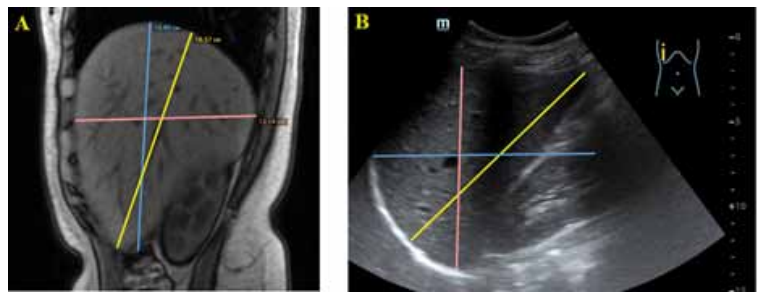
CC diameter of the left liver lobe could be considered comparable in men and women. In women AP diameter of the left lobe and thickness of the CL on average by 15–20% less than in men. Additionally, the difference between all diameters does not depend on the imaging technique.

OCC max diameter are almost the same by MRI and US for women as well as for men. However, in men this diameter more on average by 7–8%. This statement is true for measurements in MCL and in AAL.

In men AP diameter using US on average by 10% less than MRI in MCL and on average by 5% in AAL. In women AP diameter of the right lobe by US on average by 10% less than using MRI in the MCL.



**Fig. 1.** Measurements of the left liver lobe in a volunteer M., 27 years old: A — MRI, B — US (transducer orientated longitudinally in the midline under xiphisternum). Yellow color indicates the anteroposterior diameter of the left lobe, blue — the craniocaudal diameter of the left lobe, pink — the thickness of the caudate lobe



**Fig. 2.** Measurements of the right liver lobe in volunteer K., 23 years old: A — MRI, B — US (transducer orientated longitudinally in the VII-X intercostal spaces in the anterior axillary line). Yellow color indicates the oblique maximum craniocaudal diameter, blue — the craniocaudal diameter, pink — the anteroposterior diameter

Measurements of AP diameter in AAL for women, by MRI and US, are comparable.

In men AP diameter of the right liver lobe on average by 10 % more than in women by MRI and US as well as in MCL and in AAL. For CC diameters of the right lobe we have mixed results that means this is the most variable diameter of the right lobe.

## CONCLUSIONS

It can be concluded that linear liver measurements statistically significant differ in men and women: anteroposterior diameter of left lobe, thickness of the caudate lobe, anteroposterior and oblique maximum craniocaudal diameters of the right lobe. In men these diameters are larger than in women.

Linear diameters of right liver lobe by ultrasound obtained in the anterior axillary line are more comparable with the same diameters by magnetic resonance imaging for males and females.

**Table 1.** Comparative average linear diameters of the left liver lobe in women and men by MRI and US ( $M \pm m$ , mm)

Imaging technique	Diameter	Women	Men	p-value
MRI	CC	93,7±2,77	94,08±2,49	p = 0.92
	AP	67,73±1,89	81,96±2,22	p < 0.001
	thickness of CL	21,17 ±0,71	24,68±0,86	p = 0.003
US	CC	92,41±3,86	91,19±3,35	p = 0.81
	AP	61,88±1,81*	77,23±2,28	p < 0.001
	thickness of CL	21,06±0,63	23,79±0,73	p = 0.007

\* — statistical significance of differences in average values between MRI and US,  $p < 0.05$

**Table 2.** Comparative average linear diameters of the right liver lobe in women and men by MRI and US ( $M \pm m$ , mm)

Imaging technique	Diameter	Women	Men	p-value
Measurements in the right MCL				
MRI	OCC max	150,4±2,58	162,56±2,57	p = 0.002
	CC	130,17±3,75	140,24±5,10	p = 0.13
	AP	125,33±2,00	139,56±2,44	p < 0.001
US	OCC max	151,19±2,91	161,81±2,48	p = 0.007
	CC	140,31±3,12*	143,46±3,23	p = 0.49
	AP	113,28±1,66**	126,73±2,30**	p < 0.001
Measurements in the right AAL				
MRI	OCC max	146,73±2,69	157,84±3,13	p = 0.01
	CC	134,93±3,96	145,56±4,39	p = 0.09
	AP	115,1±1,93	131,16±2,62	p < 0.001
US	OCC max	152,52±3,15	164,92±2,68	p = 0.004
	CC	140,00±3,58	150,77± 3,02	p = 0.03
	AP	110,71±1,83	122,85±2,29 *	p < 0.001

\* — statistical significance of differences in average values between MRI and US,  $p < 0.05$

\*\* — statistical significance of differences in average values between MRI and US,  $p < 0.001$

## REFERENCES

1. **DITTRICH M., MILDE S., DINKEL E., BAUMANN W., WEITZEL D.**: Sonographic biometry of liver and spleen size in childhood. *Pediatr Radiology*. 1983; 13: 206–211. DOI: 10.1007/BF00973157
2. **SILVA R.M., PEREIRA R.B., SIQUEIRA M.V.** Correlation between clinical evaluation of liver size versus ultrasonography evaluation according to body mass index (BMI) and biotypes. *Rev Med Chil*. 2010; 138: 1495–501. DOI:10.4067/S0034-98872010001300004
3. **MOURATEV G., HOWE D., HOPPMANN R., POSTON M.B., REID R., VARNADOE J., SMITH S., MCCAL-**

**LUM B., RAO V., DEMARCO P.** Teaching medical students ultrasound to measure liver size: comparison with experienced clinicians using physical examinations alone. *Teach Learn Med*. 2013; 25(1): 84–88. DOI: 10.1080/10401334.2012.741535

4. **CHILDS J.T., ESTERMAN A.J., THOIRS K. A., TURNER R.C.** Ultrasound in the assessment of hepatomegaly: a simple technique to determine an enlarged liver using reliable and valid measurements. *Sonography*. 2016; 3 (2), 47–52. DOI: 10.1002/sono.12051
5. **BREDELLA M.A.** Sex Differences in Body Composition. *Advances in Experimental Medicine and Biology*. 2017; 1043: 9–27. DOI: 10.1007/978-3-319-70178-3\_2
6. **WOLF D.C., WALKER H.K., HURST J. W.** Evaluation of the Size, Shape, and Consistency of the Liver. *Clinical Methods: The History, Physical, and Laboratory Examinations*. 3rd edition. Boston: Butterworths; 1990; Chapter 94. 478–481.