

SPECIFIC FEATURES OF GRINDER TEETH ROTATION AT PHYSIOLOGICAL OCCLUSION OF VARIOUS GNATHIC DENTAL ARCHES

Article history:
Submitted 13 April 2019
Accepted 1 July 2019

Vladimir Shkarin¹, Vasily Grinin², Ruslan Halfin³,
Sergey Dmitrienko^{4*}, Dmitry Domenyuk⁵

¹ Department of public health and postgraduate education, Volgograd state medical university, Volgograd, Russia

² Department of Public Health and Health Care, First Sechenov Moscow State Medical University, Moscow, Russia

³ Graduate School of Health Management, First Sechenov Moscow State Medical University, Moscow, Russia

⁴ Department of Dentistry, Pyatigorsk Medical-Pharmaceutical Institute (Branch of Volgograd State Medical University, Pyatigorsk, Stavropol Region, Russia)

⁵ Department of General Dentistry and Child Dentistry, Stavropol State Medical University, Stavropol, Russia

*Corresponding Author: s.v.dmitrienko@pmedpharm.ru

ABSTRACT — The article offers a view on the outcomes of analyzing the convergence angles of conditional occlusal midlines passing through the middle of the occlusal surface and intersecting with the median sagittal plane, which allows determining the specifics of the upper and lower jaws grinder teeth rotation. The subject of the study was the cast models of the jaws obtained from 64 persons with physiological occlusion, a full set of permanent teeth and various gnathic (mesognathia, brachygnathia, dolichognathia), and dental (macrodontia, normodontia, microdontia) types of dental arches. Detailed examination of the data regarding grinder teeth rotation in view of the gnathic and dental type of dental arches in people with physiological occlusion, allowed us to develop, substantiate and test an examination algorithm for patients with torsioversion to be found in almost all types of anomalies and deformations of dental arches. This algorithm allowed increasing the reliability of measurements (linear, angular) in the transversal plane; identifying the degree of complexity, and selecting the treatment tactics; describing the variability of the convergence angles for grinder teeth with different gnathic and dental types of dental arches, and evaluating the effectiveness of orthodontic treatment in patients featuring dentition abnormalities and deformations.

KEYWORDS — teeth torsioversion; physiological occlusion; tooth convergence angle; gnathic, dental type of dental arches; biometry of jaws cast models.

INTRODUCTION

Lack of teeth rotation (torsioversion, torto-occlusion) is one of “the six keys to normal occlusion” proposed by Andrews L.F. in 1967 [1]. That was men-

tioned by specialists who described the major types of physiological occlusal relationships [2, 3, 4].

Based on the occlusion keys, the major gnathic and dental arches types were identified where the basic parameters were offered in the sagittal and transversal directions. The obtained data allowed the authors to identify wide, narrow and medium dental arches [5, 6]. There has been a relationship detected between the main dimensions of the dental arches and the facial parameters, which is reflected in the modern face and dental arches classifications [7, 8, 9].

Numerous studies have revealed age- and race-related features of the craniofacial structure [10,11]. Gender-bound dimorphism of human dental arches in view of the head measurements has been identified [12, 13].

This, in turn, determined the indications for the choice of orthodontic and orthopedic treatment methods, taking into account individual specifics of the dental system [14, 15, 16]. The effectiveness of the proposed research methods for treating children with congenital face and jaw disorders has been demonstrated [17, 18].

Modern methods of biometric study of jaws cast models are diverse, reliable and meet the examination standards for people with different anomalies [19, 20]. The data of a biometric study focusing on jaw models served the basis for mathematical modeling and graphic construction of individual shapes of dental arches [21–30]. Methods of X-ray examination, including cone-beam computed tomography for studying dental arches, jaw bones and the craniofacial complex as a whole [31, 32, 33, 34], have been proposed. The need for studying the temporomandibular joint has been demonstrated taking into account the front teeth location and the dental arches shape [35, 36].

The variety of research methods and clinical types of maxillofacial anomalies urge the authors to developing examination algorithms that are recommendatory in nature [37–43]. Torsioanomalies have been observed in almost all types of dental arches anomalies and deformations; however, there is virtually no information available regarding the methods for determining this anomaly [44–52]. In the available literature, we found no data on teeth rotation magni-

tude at physiological occlusion, which determined the aim of our study.

Aim of study:

to identify the specifics of grinder teeth rotation at physiological occlusion of various gnathic types of dental arches.

MATERIALS AND METHODS

The study involved 64 persons with physiological occlusion and a full set of permanent teeth. The studies were carried out in an age group belonging to the first mature age (21–35 years), in view of the biomedical ethics principles with a voluntary informed consent obtained. The patients were divided into three groups depending on the dental arches shape. 20 people of Group 1 had the shape of the dental arches identified as wide, while the gnathic and dental indicators corresponded to mesognathic macrodontic, brachygnathic normodontic and brachygnathic macrodontic types of dental arches. Group 2 included 23 persons with a medium size of the dental arches, while the main types of dental arches were mesognathic normodontic, brachygnathic normodontic and dolichognathic macrodontic ones. Group 3 consisted of 21 patients with narrow dental arches, which were to be found in people with mesognathic microdontic, dolichognathic micro- and normodontic types, which is consistent with the classification of experts who pointed at the size of dental arches as an important factor for selecting the treatment method [2].

All the patients received cast models of the jaws, which were photographed for further analysis. On the photograph, in occlusion norm, reference points and lines were applied. In the transversal direction, a line was drawn connecting the points located on the distal vestibular tubercles, than the center of the line was identified, where the reference point was set. That point was connected to the interincisal (central) point of the dental arch located between the medial incisors near the crowns occlusal contour. The resulting line was marked as the median sagittal plane (line) of the dental arch in question (Fig. 1).

On each tooth's vestibular and lingual surface, the midpoints position was identified with target points put, through which the median occlusal lines were drawn until the intersection with the model median sagittal line. The convergence angles of the indicated lines were measured. The data obtained through the study were subjected to statistical processing using the methods of parametric and non-parametric analysis following the outcomes of testing the compared sets for their normal distribution. The statistical analysis was performed using IBM SPSS Statistics 23 software.

RESULTS AND DISCUSSION

The study of the dental arches allowed obtaining data on grinder teeth rotation in view of the gnathic type of dental arches in people with physiological occlusion. It showed that the lateral teeth are located in the dental arch in such a way that their chewing surface' conditional occlusal midlines intersect in the mid-sagittal plane projection thus shaping an angle turned towards the front teeth. During that, the convergence angle of the first premolars in people with wide dental arches was $120.21 \pm 1.28^\circ$, with medium dental arches it was $125.13 \pm 1.16^\circ$, and for narrow arches the similar index was $130.09 \pm 1.28^\circ$. Moving further away from the dental arch center towards the lateral teeth, the convergence angle increased, and for the second upper premolars, its size in case of wide arches was $125.13 \pm 1.22^\circ$, for the medium arches it was $130.11 \pm 1.12^\circ$, and in people with narrow dental arches the value was $135.08 \pm 1.31^\circ$. A similar pattern was observed for the first molars located sixth in the dental arch. In case of wide, medium and narrow arches, the convergence angle was $135.23 \pm 1.14^\circ$, $140.03 \pm 1.08^\circ$ and $145.13 \pm 1.06^\circ$, respectively. The upper jaw second molars had the largest rotation of all the grinding teeth. At the same time, the convergence angle in people with wide dental arches was within $144.84 \pm 1.31^\circ$. With medium and narrow types of dental arches, the angle was $150.02 \pm 1.34^\circ$ and $155.11 \pm 1.43^\circ$, respectively (Fig. 2).

Therefore, the upper jaw grinding teeth feature the rotation of the mesial part to the median sagittal. The rotation was the highest in people with wide arches where the convergence angle of the conditional occlusal midline of the chewing surface was the smallest. In case of narrow dental arches, the rotation was the lowest in case of an increased convergence angle.

A similar situation was observed in the lower jaw grinding teeth (Fig. 3).

The rotation of the first lower premolars in people with wide arches was higher than in people with narrow dental arches. The convergence angle was $125.16 \pm 1.19^\circ$ and $134.88 \pm 1.25^\circ$, respectively ($p \leq 0.05$). In patients with medium dental arches, the convergence of conditional occlusal lines was $130.05 \pm 1.27^\circ$. In the second premolars, compared with the first ones, the rotation increased, which led to an increase in the convergence angle: $130.21 \pm 1.17^\circ$ for wide dental arches; $135.26 \pm 1.24^\circ$ for medium arches, and in cases with narrow dental arches it was $145.18 \pm 1.26^\circ$. For the first lower molars with wide, medium and narrow dental arches, the convergence angle was $139.83 \pm 1.21^\circ$, $144.94 \pm 1.09^\circ$ and $150.04 \pm 1.14^\circ$, respectively. For the second lower molars, the convergence of teeth with

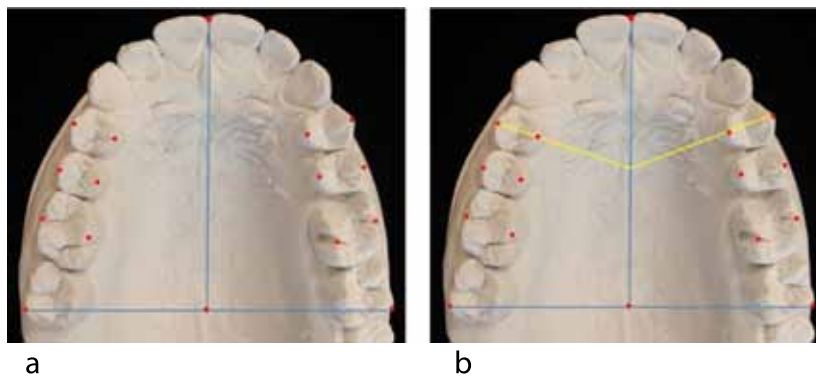


Fig. 1. Applying reference lines and points on the model image (a) to identify the convergence angle for median occlusal lines (b)

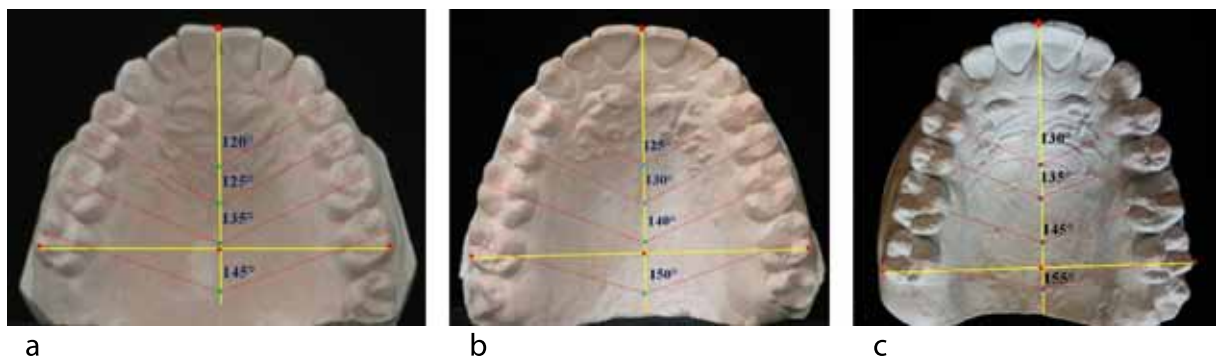


Fig. 2. Rotation specifics of upper jaw teeth in people with wide (a), medium (b) and narrow (c) dental arches

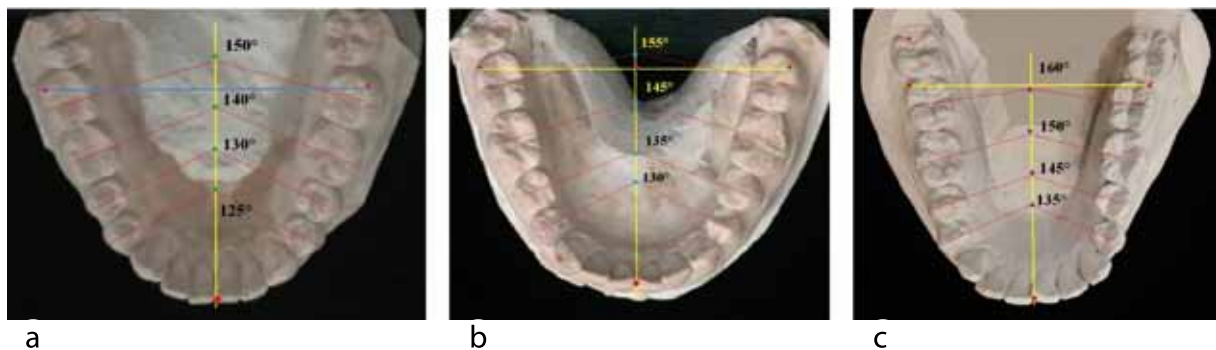


Fig. 3. Rotation specifics for lower jaw teeth in people with wide (a), median (b) and narrow (c) dental arches

wide dental arches was $150.12 \pm 1.14^\circ$. With medium and narrow types of dental arches, the angle was $154.99 \pm 1.31^\circ$ and $160.16 \pm 1.02^\circ$, respectively.

Given the above, as far as the lower jaw is concerned, almost all the parameters that determine the teeth rotation, were on average 5 degrees above those relate to the antagonists.

CONCLUSIONS

1. Based on the measurement of the convergence angle for the conditional lines passing through the

middle of the occlusal surface and intersecting the median sagittal plane, the new method for identifying the grinder teeth rotation is reliable, diagnostically meaningful, and can be employed as an additional criterion to describe the physiological occlusion of dental arches belonging to various gnathic types, for diagnosing lateral teeth torsioanomalies, as well as for evaluating the effectiveness of orthodontic treatment in patients with dentofacial pathology.

2. Regardless of the gnathic and dental types of arches of both jaws, almost the all indicators that

determine the teeth rotation in the lower jaw exceed similar parameters in the upper jaw, on average by 5 degrees, which can be used in clinical orthodontics to identify treatment tactics and its effectiveness in people with various gnathic and dental types of arches.

3. The introduction into clinical orthodontics the data obtained through this study regarding the convergence angles for the upper and lower jaws premolars and molars in patients with various gnathic and dental types of arches, will allow reducing the time spent at the early diagnostics stage, and improve the efficiency of monitoring the orthodontic correction outcomes.

4. People with wide dental arches with the smallest convergence angle of the grinding surface conditional occlusal median lines feature the highest level of the grinding teeth rotation in both jaws. People with narrow dental arches who had the largest convergence angle were found to have the lowest grinding teeth rotation in both jaws.

5. Improving the existing methods used for diagnosing dental anomalies resulted in the development of algorithms that can be employed to examine patients with torsioanomalies that occur in virtually all types of dental arches issues and deformations, and introducing the algorithms in question may allow not only optimizing biometric instrumental measurement techniques on cast jaw models yet also ensuring optimal functional and aesthetic results due to the predictability of orthodontic treatment.

REFERENCES

1. **ANDREWS L.F.** The six keys to normal occlusion. *Am. J. Orthodont.* 1972. 62. P. 296.
2. **DMITRIENKO S.V., DOMENYUK D.A., KOCHKONYAN A.S., KARSLIEVA A.G., DMITRIENKO D.S.** Modern classification of dental arches // *Archiv EuroMedica*, 2014. Vol. 4. № 2. P. 14–16.
3. **DMITRIENKO S.V., DOMENYUK D.A., KOCHKONYAN A.S., KARSLIEVA A.G., DMITRIENKO D.S.** Interrelation between sagittal and transversal sizes of maxillary dental arches // *Archiv EuroMedica*, 2014. Vol. 4. № 2. P. 10–13.
4. **DMITRIENKO S.V., DOMENYUK D.A., VEDESHINA E.G.** Shape individualization in lower dental arches drawn on basic morphometric features // *Archiv EuroMedica*, 2015. Vol. 5. № 1. P. 11.
5. **KOROBKEEV A.A., DOMENYUK D.A., SHKARIN V.V., DMITRIENKO S.V., WEISHEIM L.D., KONNOV V.V.** Anatomical features of the interdependence of the basic parameters of the dental arches of the upper and lower jaws of man. *Medical news of North Caucasus*. 2018. – Vol. 13. – № 1–1. – P. 66–69. (In Russ., English abstract). DOI – <https://doi.org/10.14300/mnnc.2018.13019>
6. **BORODINA V.V., DOMENYUK D.A., WEISHEIM L.D., DMITRIENKO S.V.** Biometry of permanent occlusion dental arches – comparison algorithm for real and design indicators // *Archiv EuroMedica*. 2018. Vol. 8. № 1. P. 25–26.
7. **DOMENYUK D.A., VEDESHINA E.G., DMITRIENKO S.V.** Correlation of dental arch major linear parameters and odontometric indices given physiological occlusion of permanent teeth in various face types // *Archiv EuroMedica*. 2016. Vol. 6; 2. P. 18–22.
8. **DOMENYUK D.A., SHKARIN V.V., PORFIRIADIS M.P., DMITRIENKO D.S., DMITRIENKO S.V.** Classification of facial types in view of gnathology // *Archiv EuroMedica*, 2017. Vol. 7; 1. P. 8–13.
9. **KOROBKEEV A.A., DOMENYUK D.A., SHKARIN V.V., DMITRIENKO S.V.** Types of facial heart depth in physiological occlusion. *Medical news of North Caucasus*. 2018. – Vol. 13; 4. – P. 627–630. (In Russ., English abstract). DOI – <https://doi.org/10.14300/mnnc.2018.13122>
10. **GORELIK E.V., DMITRIENKO S.V., IZMAYLOVA T.I., KRAYUSHKIN A.I.** Features of the craniofacial complex in different age periods // *Morphology*. 2006. № 4. P. 39.
11. **DMITRIENKO S.V., KRAYUSHKIN A.I., DMITRIENKO D.S., EFIMOVA E.YU.** Topographic-anatomical features of the structure of the bone tissue of the mandibular segments // *Dentistry*. 2007. Vol. 86; 6. P. 10–12.
12. **SHKARIN V.V., DOMENYUK D.A., LEPILIN A.V., FOMIN I.V., DMITRIENKO S.V.** Odontometric indices fluctuation in people with physiological occlusion // *Archiv EuroMedica*, 2018. Vol. 8. № 1. P. 12–18.
13. **KOROBKEEV A. A., DOMENYUK D. A., SHKARIN V. V., DMITRIENKO S. V., MAZHAROV V. N.** Variability of odontometric indices in the aspect of sexual dimorphism. *Medical News of North Caucasus*. 2019;14(1.1):103–107. DOI – <https://doi.org/10.14300/mnnc.2019.14062> (In Russ.)
14. **DOMENYUK D.A., VEDESHINA E.G., DMITRIENKO S.V.** Efficiency evaluation for integrated approach to choice of orthodontic and prosthetic treatments in patients with reduced gnathic region // *Archiv EuroMedica*. 2015. Vol. 5; 2. P. 6–12.
15. **DMITRIENKO S.V., DOMENYUK D.A., FISCHEV S.B., SUBBOTIN R.S.** Dynamics of periodontal fixing capacity through orthodontic treatment employing edgewise technique // *Archiv EuroMedica*. 2019. Vol. 9; 1: 151–152. <https://doi.org/10.35630/2199-885X/2019/9/1/151>
16. **DMITRIENKO S.V., DOMENYUK D.A., PUZDYRYOVA M.N.** Manufacturing methods for individual aligners and trainers from thermoplasts find clinical indications for their application // *Archiv EuroMedica*. 2019. Vol. 9; 1: 153–154. <https://doi.org/10.35630/2199-885X/2019/9/1/153>
17. **SHKARIN V.V., DAVYDOV B.N., DOMENYUK D.A., DMITRIENKO S.V.** Non-removable arch orthodontic appliances for treating children with congenital maxillofacial pathologies – efficiency evolution // *Archiv*

- EuroMedica, 2018. Vol. 8; 1. P. 97–98. <https://doi.org/10.35630/2199-885X/2018/8/1/97>
18. **DMITRIENKO S.V., PORFYRIADIS M.P., DOMENYUK D.A., BUDAYCHIEV G.M.-A.** Dentoalveolar specifics in children with cleft palate during primary occlusion period // *Archiv EuroMedica*, 2018. Vol. 8. № 1. P. 33–34.
 19. **DOMENYUK D.A., VEDESHINA E.G., DMITRIENKO S.V.** Mistakes in Pont (Linder-Hart) method used for diagnosing abnormal dental arches in transversal plane // *Archiv EuroMedica*. 2016. Vol. 6. № 2. P. 23–26.
 20. **DOMENYUK D.A., LEPILIN A.V., FOMIN I.V., DMITRIENKO S.V., BUDAYCHIEV G.M.-A.** Improving odontometric diagnostics at jaw stone model examination // *Archiv EuroMedica*. 2018. Vol. 8; 1. P. 34–35. <https://doi.org/10.35630/2199-885X/2018/8/1/34>
 21. **SHKARIN V.V., DOMENYUK D.A., PORFYRIADIS M.P., DMITRIENKO D.S., DMITRIENKO S.V.** Mathematical and graphics simulation for individual shape of maxillary dental arch // *Archiv EuroMedica*, 2017. Vol. 7. № 1. P. 60–65.
 22. **PORFYRIADIS M.P., DMITRIENKO S.V., DOMENYUK D.A., BUDAYCHIEV G.M.-A.** Mathematic simulation for upper dental arch in primary teeth occlusion // *Archiv EuroMedica*, 2018. Vol. 8; 1. P. 36–37.
 23. **LEPILIN A.V., RAJGORODSKIY YU.M., GRIGORYEVA D.A., EROKINA N.L., BAKHTEEVA G.R., DOMENYUK D.A.** Reasoning for the application of violet laser physiotherapy device following surgeries in the oral cavity. *Archiv EuroMedica*, 2018; 8(2): 111–114.
 24. **DOMENYUK D.A., ZELENSKY V.A., RZHEPAKOVSKY I.V., ANFINOGENOVA O.I., PUSHKIN S.V.** Application of laboratory and x-ray general studies un early diagnostics of metabolic disturbances of bone tissue in children with autoimmune diabetes mellitus. *Entomology and Applied Science Letters*. 2018; 5(4): 1–12.
 25. **DOMENYUK D.A., KONNOV V.V., PICHUGINA E.N., ANFINOGENOVA O.I., GONCHARENKO A.N., PUSHKIN S.V.** Microcomputed tomography in qualitative and quantitative evaluation of dental enamel demineralization. *Entomology and Applied Science Letters*. 2018; 5(4): 72–83.
 26. **DMITRIENKO S.V., LEPILIN A.V., FOMIN I.V., DOMENYUK D.A., DAVYDOV B.N.** Study of morphology, methods of comparison of tooth and alveolar arcs by results of anthropometry and cellular-beam computer tomography (Part I). *The Dental Institute*. 2018; 79(2): 68–72. (In Russ.).
 27. **PORFYRIADIS M.P., DOMENYUK D.A., DAVYDOV B.N., DMITRIENKO S.V., BUDAYCHIEV G.M.-A.** Variability of cephalometric indices in men and women with mesocefalic form of the head and various constitutional types of face (Part II). *The Dental Institute*. 2018; 79(2): 82–85. (In Russ.).
 28. **DMITRIENKO S.V., DOMENYUK D.A.** Dentoalveolar specifics in children with cleft palate during primary occlusion period. *Archiv EuroMedica*, 2018; Vol. 8; 1: 33–34.
 29. **PORFYRIADIS M.P., DOMENYUK D.A., DAVYDOV B.N., DMITRIENKO S.V., BUDAYCHIEV G.M.-A.** Variability of cephalometric indices in men and women with mesocefalic form of the head and various constitutional types of face (Part I). *The Dental Institute*. 2018; 78(1): 70–73. (In Russ.).
 30. **ZELENSKY, V.A.** Integral indicator for orthodontic carequality control / V.A. Zelensky, D.A. Domenyuk, M.V. Baturin, I.V. Zelensky, A.V. Kokareva, A.V. Zenina // *Medical news of North Caucasus*. 2014. – Vol. 9. – № 1. – P. 80–83. (In Russ., English abstract). DOI: 10.14300/mnnc.2014.09022.
 31. **DOMENYUK D.A., DMITRIENKO S.V., PORFYRIADIS M.P.** Major telerehengogram indicators in people with various growth types of facial area // *Archiv EuroMedica*. 2018. Vol. 8; 1: P. 19–24. <https://doi.org/10.35630/2199-885X/2018/8/1/19>
 32. **LEPILIN A.V., FOMIN I.V., DOMENYUK D.A., DMITRIENKO S.V., BUDAYCHIEV G.M.-A.** Diagnostic value of cephalometric parameters at graphic reproduction of tooth dental arches in primary teeth occlusion // *Archiv EuroMedica*, 2018. Vol. 8. № 1. P. 37–38.
 33. **DMITRIENKO T.D., DOMENYUK D.A., PORFYRIADIS M.P., ARUTYUNOVA A.G., KONDRATYUK A.A., SUBBOTIN R.S.** Connection between clinical and radiological torque of medial incisor at physiological occlusion // *Archiv EuroMedica*. 2019. Vol. 9; 1: P. 29–37. <https://doi.org/10.35630/2199-885X/2019/9/1/29>
 34. **PORFYRIADIS M.P., DOMENYUK D.A., ARUTYUNOVA A.G., DMITRIENKO S.V.** Scanning electron microscopy and X-ray spectral microanalysis in dental tissue resistance // *Archiv EuroMedica*. 2019. Vol. 9; 1: 177–185. <https://doi.org/10.35630/2199-885X/2019/9/1/177>
 35. **DMITRIENKO S.V., FOMIN I.V., DOMENYUK D.A., KONDRATYUK A.A., SUBBOTIN R.S.** Enhancement of research method for spatial location of temporomandibular elements and maxillary and mandibular medial incisors // *Archiv EuroMedica*. 2019. Vol. 9; 1: P. 38–44. <https://doi.org/10.35630/2199-885X/2019/9/1/38>
 36. **DMITRIENKO S.V., LEPILIN A.V., DOMENYUK D.A., KONDRATYUK A.A.** Clinical meaning of methods for identifying variability of mental prominence location // *Archiv EuroMedica*. 2019. Vol. 9; 1: 45–46. <https://doi.org/10.35630/2199-885X/2019/9/1/45>
 37. **DOMENYUK D.A., SHKARIN V.V., PORFYRIADIS M.P., DMITRIENKO D.S., DMITRIENKO S.V.** Algorithm for forecasting the shape and size of dent arches front part in case of their deformations and anomalies // *Archiv EuroMedica*, 2017. Vol. 7; 1: P. 105–110.
 38. **DMITRIENKO S.V., DAVYDOV B.N., V.V. SHKARIN, DOMENYUK D.A.** Algorithm for determining the size of artificial teeth by the morphometric parameters of the face in people with full adentia. *Dentistry*. 2018; 97(6): 57–60. DOI – 10.17116/stomat20189706157

39. DOMENYUK D.A., PORFYRIADIS M.P., BUDAYCHIEV G. M.-A. Contemporary methodological approaches to diagnosing bone tissue disturbances in children with type 1 diabetes. *Archiv EuroMedica*, 2018; 8(2): 71–81. <https://doi.org/10.35630/2199-885X/2018/8/2/71>
40. DAVYDOV B.N., DOMENYUK D.A., DMITRIENKO S.V. Peculiarities of microcirculation in periodont tissues in children of key age groups sufficient type 1 diabetes. Part I. *Periodontology*, 2019; Vol. 24; 1–24(90): 4–10. DOI: 10.25636/PMP.1.2019.1.1
41. DAVYDOV B.N., DOMENYUK D.A., DMITRIENKO S.V. Peculiarities of microcirculation in periodont tissues in children of key age groups sufficient type 1 diabetes. Part II. *Periodontology*, 2019; Vol. 24; 2–24(91): 108–119. DOI: 10.33925/1683-3759-2019-24-2-108-119
42. DAVYDOV B.N., DOMENYUK D.A., BYKOV I.M., IVCHENKO L.G., DMITRIENKO S.V. Modern possibilities of clinical-laboratory and x-ray research in pre-clinical diagnostics and prediction of the risk of development of periodontal in children with sugar diabetes of the first type. Part I. *Periodontology*, 2018; Vol. 23; 3–23(88): 4–11. DOI:10.25636/PMP.1.2018.3.1
43. DOMENYUK D.A., DAVYDOV B.N., DMITRIENKO S.V., SUMKINA O.B., BUDAYCHIEV G. M.-A. Changes of the morphological state of tissue of the paradontal complex in the dynamics of orthodontic transfer of teeth (experimental study). *Periodontology*, 2018; Vol. 23; 1–23(86): 69–78. DOI:10.25636/PMP.1.2018.1.15
44. DOMENYUK D.A., ZELENSKY V.A., DMITRIENKO S.V., ANFINOGENOVA O.I., PUSHKIN S.V. Peculiarities of phosphorine calcium exchange in the pathogenesis of dental caries in children with diabetes of the first type // *Entomology and Applied Science Letters*. 2018. Vol. 5. № 4. P. 49–64.
45. FISCHEV S.B., PUZDYRYOVA M.N., DMITRIENKO S.V., DOMENYUK D.A., KONDRATYUK A.A. Morphological features of dentofacial area in peoples with dental arch issues combined with occlusion anomalies // *Archiv EuroMedica*. 2019. Vol. 9; 1: 162–163. <https://doi.org/10.35630/2199-885X/2019/9/1/162>
46. LEPILIN A.V., DMITRIENKO S.V., DOMENYUK D.A., PUZDYRYOVA M.N., SUBBOTIN R.S. Dependence of stress strain of dental hard tissues and periodontal on horizontal deformation degree // *Archiv EuroMedica*. 2019. Vol. 9; 1: 173–174. <https://doi.org/10.35630/2199-885X/2019/9/1/173>
47. SHKARIN V.V., PORFYRIADIS M.P., DOMENYUK D.A., DMITRIENKO D.S., DMITRIENKO S.V. Setting reference points for key teeth location in case of abnormal dental arch shape // *Archiv EuroMedica*. 2017. Vol. 7; 1: P. 111–117.
48. DAVYDOV B.N., DOMENYUK D.A., DMITRIENKO S.V., KOROBKEEV A.A., ARUTYUNOVA A.G. Morphological peculiarities of facial skelet structure and clinical and diagnostic approaches to the treatment of dental anomalies in children in the period of early change. *Pediatric dentistry and prevention*. 2019; Vol. 19; 1 (69): 26–38. (In Russ.) DOI: 10.33925/1683-3031-2019-19-69-26-38
49. PORFYRIADIS M.P., DOMENYUK D.A., DAVYDOV B.N., DMITRIENKO S.V., BUDAYCHIEV G.M.-A. Variability of cephalometric indices in men and women with mesocefalic form of the head and various constitutional types of face (Part III). *The Dental Institute*. 2018; 80(3): 84–87. (In Russ.).
50. DMITRIENKO S.V., LEPILIN A.V., FOMIN I.V., DOMENYUK D.A., DAVYDOV B.N. Study of morphology, methods of comparison of tooth and alveolar arcs by results of anthropometry and cellular-beam computer tomography (Part II). *The Dental Institute*. 2018; 80(3): 70–74. (In Russ.).
51. DOMENYUK D.A., DAVYDOV B.N., DMITRIENKO S.V., LEPILIN A.V., FOMIN I.V. Diagnostic opportunities of cone-box computer tomography in conducting craniomorphological and craniometric research in assessment of individual anatomical variability (Part I). *The Dental Institute*. 2018; 81(4): 52–55. (In Russ.).
52. DOMENYUK D.A., DAVYDOV B.N., DMITRIENKO S.V., LEPILIN A.V., FOMIN I.V. Diagnostic opportunities of cone-box computer tomography in conducting craniomorphological and craniometric research in assessment of individual anatomical variability (Part I). *The Dental Institute*. 2019; 82(1): 72–76. (In Russ.).